Clinical Article

Long-term Follow-up Results of Short-segment Posterior Screw Fixation for Thoracolumbar Burst Fractures

Yoon-Soo Lee, M.D., Joo-Kyung Sung, M.D.
Department of Neurosurgery, School of Medicine, Kyungpook National University, Daegu, Korea

Objective : Despite general agreement on the goals of surgical treatment in thoracolumbar burst fractures, considerable controversy exists regarding the choice of operative techniques. This study is to evaluate the efficacy of short-segment fixation for thoracolumbar burst fractures after long-term follow-up and to analyze the causes of treatment failures.

Methods : 48 out of 60 patients who underwent short-segment fixation for thoracolumbar burst fractures between January 1999 and October 2002 were enrolled in this study. Their neurological status, radiological images, and hospital records were retrospectively reviewed. Simple radiographs were evaluated to calculate kyphotic angles and percentages of anterior body compression (%ABC).

Results : The average kyphotic angles were 20.0° preoperatively, 9.6° postoperatively, and 13.1° at the latest follow-up. The average %ABC were 47.3% preoperatively, 31.2% postoperatively, and 33.3% at the latest follow-up. The treatment failure, defined as correction loss by 10° or more or implant failure, was detected in 6 patients (12.5%). 5 out of 6 patients had implant failures. 2 out of 5 patients were related with osteoporosis, and the other 2 were related with poor compliance of spinal bracing. 3 patients with poor initial postoperative alignment had implant failure. 4 patients with screws only on the adjacent vertebrae and not on the injured vertebra itself showed poor initial and overall correction.

Conclusion : With proper patient selection, adequate intraoperative reduction with screw fixation involving the injured vertebra, and strict postoperative spinal bracing, the short-segment fixation is an efficient and safe method in the treatment of thoracolumbar burst fracture.

KEY WORDS : Thoracolumbar burst fracture · Short-segment fixation · Kyphotic angle · Implant failure.

Introduction

The goals of surgical treatment in thoracolumbar burst fractures are decompression of neural element, restoration of vertebral height and alignment, stabilization, and early mobilization in order to acquire maximal recovery from neurological and functional deficits in the long run. Despite general agreement on the goals of surgical treatment, considerable controversy exists in the choice of operative techniques: short-segment fixation versus long-segment fixation, anterior approach versus posterior approach, bone grafting versus no bone grafting, and so forth[4,7,15,37].

The most important advantage of short-segment fixation over long-segment fixation is to preserve motion segments. On the other hand, long-segment fixation can achieve relatively closer alignment to a normal spinal line and maintain firmer fixation even in a situation when single level of fixation is to fail. Therefore, according to recent reports, short-segment fixation is generally indicated for young and active patients in whom an extensive segment of arthrodesis would result in detrimental effect on motion and for patients in whom good compliance with postoperative spinal bracing is expected[27,28,31]. Long-segment fixation is indicated for patients with complete cord injury, elderly patients with pre-existing degenerative disease who are not likely to get benefit from sparing intervertebral motion, and patients with poor compliance to wear postoperative spinal brace[27,28,31].

Although there have been several reports dealing with short-segment fixation, they are lack of long-term follow-up to validate the safety and efficacy of this instrumentation. Several recent reports also have mentioned the failures in short-segment fixation[2,3,18,23,27,28,35]. However, the causes of failures have not yet been evaluated adequately. This study is to evaluate the efficacy of short-segment fixation for thoracolumbar burst fractures after long-term follow-up and to analyze the causes of treatment failures.

• Received : August 30, 2004 • Accepted : November 30, 2004
• Address for reprints : Joo-Kyung Sung, M.D., Department of Neurosurgery, School of Medicine, Kyungpook National University, 50 Samdeok-2-ga, Jung-gu, Daegu 700-721, Korea
Tel : +82.53-420-5655, Fax : +82.53-423-0504
E-mail : jksung@knu.ac.kr

Materials and Methods

Between January 1999 and October 2002, 60 patients with thoracolumbar burst fractures in T12 to L2 were treated with short-segment pedicle screw fixation. Twelve out of 60 patients were lost to follow-up and 48 patients were enrolled in this study. There were 22 males and 26 females. Their ages ranged from 20 to 73years (mean 42.1years) (Fig. 1). Twenty-nine patients fell from height, 2 patients were struck by heavy objects, and the remaining 17 patients were injured in motor vehicle accidents. Their injury levels were T12 in 11 cases, L1 in 29 cases, and L2 in 8 cases.

Indications for operations were progressive neurological deficit, kyphosis more than 20°, loss of vertebral body height by more than 50%, compromise of spinal canals, and any other evidence of instability which are based on the criteria of unstable burst fracture by McAfee et al[26].

All operations were performed by standard midline posterior approach. Decompressive total laminectomy was performed in all cases and free bone fragments in spinal canal were pushed back into the original position by using bone impactor when required. A level of vertebrae above and below the injured vertebra were stabilized using pedicular screws and rods, including the level of injured vertebra in 44 out of 48 cases. In the other 4 cases, severely destroyed pedicles or vertebral bodies made the procedure impossible. Autogenous posterolateral bone grafting was performed after completion of the fixation procedure. The bone graft materials were obtained from the laminae and the spinous processes after laminectomies, but autogenous iliac bones or allografts were not used[19,22].

After the operations, all patients were requested to wear thoracolumbar orthosis for 3months or more. They were braced and ambulated as soon as they regained trunk motion control to prevent complications of prolonged bed rest.

Their preoperative neurological status and late follow-up status after surgery were recorded according to Frankel's grade[16]. Radiological images and hospital records including operative records were retrospectively reviewed. The duration of follow-up averaged 26.8months and ranged from 17 to 52months.

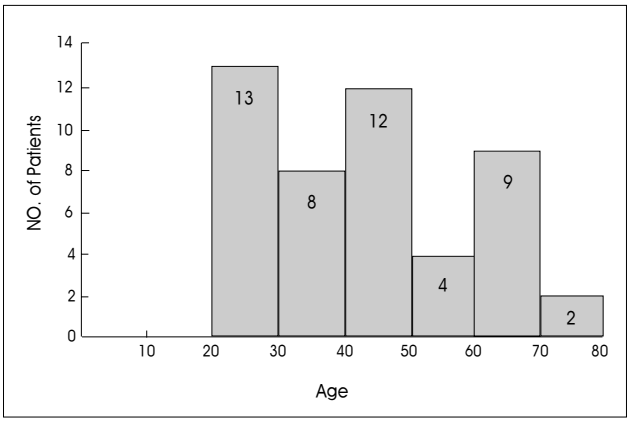

Fig. 1. The age distribution of the patients with thoracolumbar burst fractures.

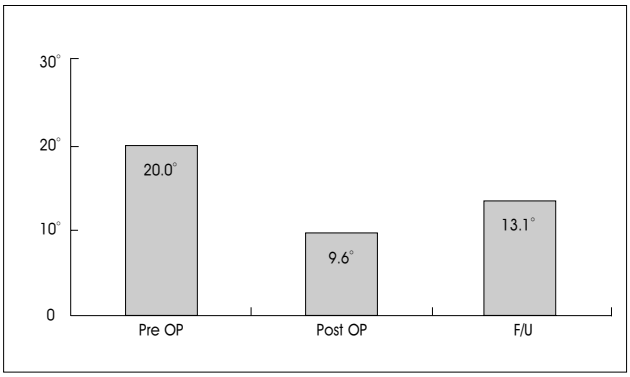

Fig. 2. The change of kyphotic angles.

Results

Kyphotic angle

Kyphotic angle was measured between the superior end-plate of the upper and the inferior end-plate of the lower non-injured vertebra by Cobb's method from the preoperative, postoperative, and follow-up lateral views of simple radiographs[39]. Average preoperative kyphotic angle was 20.0°, and was corrected to 9.6° postoperatively, but progressed to 13.1° at the latest follow-up (Fig. 2, 3). Six patients (12.5%) had correction loss of more than 10° in kyphotic angle in the latest follow-up radiographs when compared with the measurement on the postoperative radiographs, and those were regarded as failed cases (Table 1)[2]. Five out of 6 failed cases had screw loosening or pull-out at the latest follow-up. Six out of 48 patients had underlying osteoporosis prior to the operations, and 3 of them had progression of kyphosis and were included in the failed cases. Two patients showed poor compliance with spinal bracing and had progression of ky-

Table 1. Changes of kyphotic angles in the success group and the failed group

	Total n=48	Success Group n=42	Failed Group n=6
Preoperative (A)	20.0°	19.6°	22.8°
Postoperative (B)	9.6°	8.3°	19.0°
Follow−Up (C)	13.1°	9.9°	35.6°
Initial Correction (A−B)	10.4°	11.3°	3.8°
Loss of Correction (C−B)	3.5°	1.6°	16.6°
Overall Correction (A−C)	6.9°	9.7°	−12.8°

phosis with marked screw loosening, which was removed later (Fig. 4).

Percentage of anterior body compression

Anterior body heights of the injured vertebra and the non-injured, adjacent vertebrae above and below the injured level were measured, and the percentage of anterior body compression (%ABC) was calculated using the formula by Mumford et al[30]. Average preoperative %ABC was 47.3%, and improved to 31.2% postoperatively, then slightly declined to 33.3% at the latest follow-up (Fig. 5).

Neurological improvement

Preoperative and follow-up neurological status after the surgery were evaluated using Frankel's grade. Preoperative status were grade A in 7 patients, grade B in 9 patients, grade C in 12 patients, grade D in 10 patients, and grade E in 10 patients. By the way, follow-up status after the surgery were grade A in 4 patients, grade B in 4 patients, grade C in 4 patients, grade D in 13 patients, and grade E in 23 patients. Thirty out of 38 patients with neurological deficits (Frankel's grade A, B, C, and D) showed neurological improvement of at least one Frankel's grade, and the other 8 patients remained in the same grade as preoperative status. No patient showed neurological deterioration after surgery (Table 2).

Implant failures and implant survival rate

Implant failures occurred in 5 cases due to screw loosening or pull-out. Three of them had minor screw loosening and did not need surgical treatment. Surgical treatments removing the screws were performed in the other 2 cases in which the screws were pulled out and palpable on the skin (Fig. 4). Other kinds of implant failures such as screw bending or breakage were not encountered. In this study, the overall implant survival rate was 89.6% at the latest follow-up after the surgery.

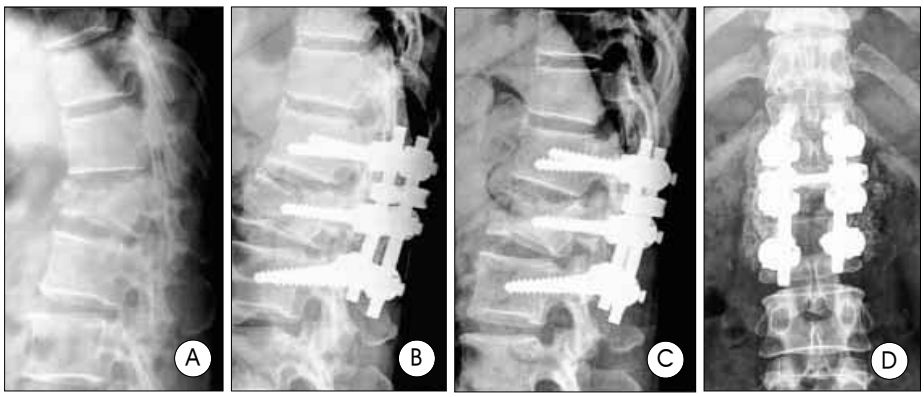

Fig. 3. Preoperative(A), postoperative(B), and 27 months follow-up(C) radiographs of the 40 year-old patient showing improvement in kyphotic angle with intact instrumentation system. Twenty-seven months follow-up anteroposterior view(D) showing excellent bone fusion after bone graft using the laminae and the spinous processes from laminectomies.

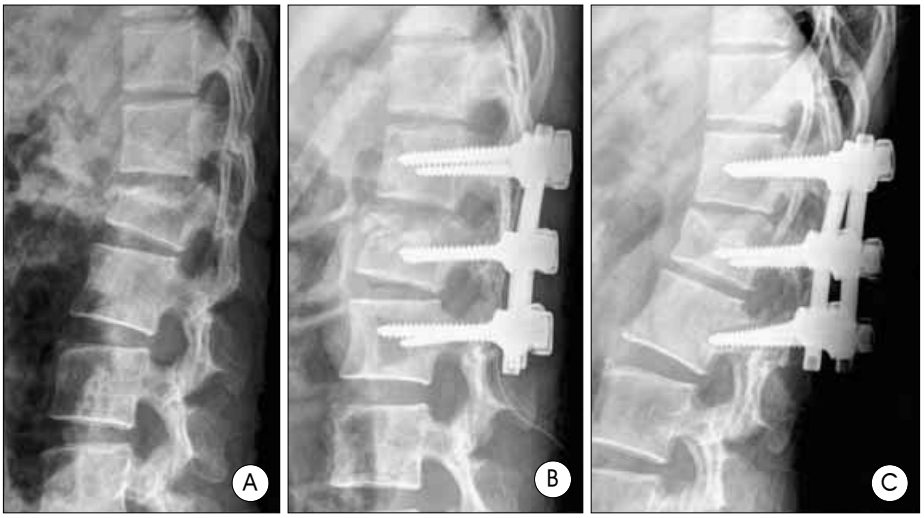

Fig. 4. Preoperative(A), postoperative(B), and 16 months follow-up(C) radiographs of the 24 year-old patient who showed poor compliance with spinal bracing. The follow-up radiograph shows progression of kyphosis with marked screw pull-out. A surgical treatment removing the screws was performed in this case.

Complications

In 11 cases (22.9%), dural tearing caused by the initial injury was encountered after laminectomy. It was sutured primarily and treated with the fibrin glue (Tisseel®). Cerebrospinal fluid did not leak postoperatively in any cases. No wound infections and systemic complications related to the operations occurred.

Discussion

Thoracolumbar burst fracture is a common injury related with fall from height and motor vehicle accident. However, there has been considerable controversy regarding the management of thoracolumbar burst fracture. The management of this fracture has been changed in last several de-

cades. In the past, thoracolumbar fracture was treated with conservative methods of cast or brace immobilization with long-term bed resting[6,13,30]. With the introduction of pedicle screw instrumentation, surgical management such as long-segment fixation became widespread which promoted early ambulation and rehabilitation, and brought significantly better improvement in terms of kyphosis and neurological outcome as most authors agreed[1,5]. With progressive improvement of spinal instrumentation systems, short-segment pedicle screw fixation was introduced which would replace long-segment pedicle screw fixation[8,12,17,20,33,36,38]. However, several recent reports revealed complications related with short-segment instrumentation such as early failure of instrument as well as delayed progression of kyphotic deformity[2,3,18,23,27,28,35]. On the other hand, other reports suggested that short-segment fixation is efficient and safe method in the treatment of thoracolumbar fracture with minimal complications[11,17,32,38]. These reports emphasized on the preservation of motion segment above and below the fusion level, simple and familiar surgical procedures, and also less invasiveness in short-segment fixation when compared with long-segment fixation.

Harrington instrumentation was the first successful method of internal fixation for spinal fracture that is long-segment dual distraction rod instrumentation[7,35]. With the advantage of early ambulation after surgical treatment in thoracolumbar fracture, the long-segment posterior fixation, involving two or three vertebrae above and below the injured one, quickly gained popularity. Increasing concern about the large number of immobilized motion segment made motivation toward short-segment screw fixation, involving one level above and below the injured vertebra. However, with the short-segment fixation, implant failure with subsequent loss of correction in kyphotic angle is the utmost concern. Considering 10° or more correction loss or implant failure as criteria of failure, the rate of failure has been reported to be 40~45% in several studies[2,3,23,27,28]. In our study, the failure rate was 12.5%, 6 out of 48 patients, and their records and radiographs were reviewed to analyze the causes of failures.

Implant failure refers to broken or bent screw, or screw loosening or pull-out. In this study, there was no broken or bent screw. Several recent reports revealed considerable rate of instrumentation breakage or bending. Daniaux et al reported 19% of screw breakage rate in the use of pedicle screw and plate system for spinal fracture patients[10]. Lindsey and Dick also reported broken screws in 5 out of 80 patients using the Fixateur Interne[24]. Esses et al reported 3 patients out of 120 with broken screws when they used the AO internal fixator[15]. Ebelke et al identified 6% of broken screws using VSP instrumentation[14]. These screw breakages or bendings are related with disruption of anterior spinal column. However, these reports were published more than 10 years ago. According to recent reports, the rates of screw breakage or bending are significantly decreased with the improvement of instrumentation. In our study, one of the newest and/or most popular versions of screw and rod systems such as Diapason, TSRH, Optima, and so forth was used, and these instrumentations would have acted as firmer systems than those of 10years ago. There were 5 cases of screw loosening in this study. Two out of 5 cases of screw loosening were related with predisposing osteoporosis, and the other 2 patients were related with poor compliance of spinal bracing. The 2 patients who did not use spinal bracing postoperatively had severe screw pull-out and needed reoperation to remove

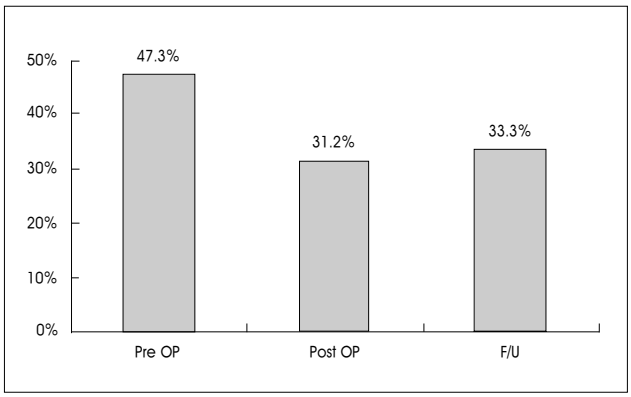

Fig. 5. The percentages of the anterior body compression.

Table 2. Neurological improvement between initial and final outcome by Frankel's Grade (n=48)

Initial \ Final	A	B	C	D	E
A	4	1	1	1	0
B	0	3	2	4	0
C	0	0	1	8	3
D	0	0	0	0	10
E	0	0	0	0	10

Table 3. Changes of kyphotic angles in the group with screw on the injured vertebra and the group without screw on the injured vertebra

	Total n=48	Group with Screw on the Injured Vertebra n=44	Group without Screw on the Injured Vertebra n=4
Preoperative (A)	20.0°	19.8°	22.6°
Postoperative (B)	9.6°	8.7°	19.2°
Follow−Up (C)	13.1°	12.0°	24.7°
Initial Correction (A−B)	10.4°	11.1°	3.4°
Loss of Correction (C−B)	3.5°	3.3°	5.5°
Overall Correction (A−C)	6.9°	7.8°	−12.1°

the whole instrumentation. In this study, the overall implant survival rate was 89.6%. From these results, we concluded that implant failures largely dep-ended on the firmness of instrumentation system, the presence of underlying degenerative disorders such as osteoporosis, and patients' compliance to wear spinal brace until the com-pletion of bone fusion.

Loss of initial correction of kyphosis after pedicle screw fixation is reported by many authors. Sasso et al, Daniaux et al, and Lindsey and Dick reported that despite of good surgical correction of kyphosis, most is lost at long-term follow-up[10,24,36]. Carl et al reported that 7.4° of correction was achieved then declined by 6.4° at the follow-up, leaving overall correction of only 1.0°[7]. Meanwhile, Razak et al reported 13° of correction and only 2° of correction loss at the follow-up[32]. Our study showed 10.4° of correction postoperatively, then 3.5° of correction loss, leaving overall 6.9° correction. This result, in my opinion, is thought to be acceptable, because this data includes severely deteriorated patients with more than overall 20° loss of kyphotic angle which could have been possibly prevented by proper patient selection.

We reviewed radiographs of 6 failed cases and found that 3 cases of them had poor initial postoperative alignment and they tended to aggravate even worse in the follow-up radiographs. Meanwhile, in the other 3 failed cases, kyphosis progressed slowly in spite of good postoperative alignment. It means that these 3 cases failed to achieve adequate intraoperative reduction which made them carry high risk of poor outcome even after the operation. Therefore, initial postoperative alignment after surgical reduction seems to be extremely important to the patient's outcome. Poor initial postoperative alignment is more likely to be related to complications such as progression of kyphosis and implant failure.

In 4 patients in this study, screw fixation was not performed to the injured vertebra itself. Screw fixation was performed only to the adjacent vertebrae for some inevitable reasons. One out of 4 patients had progression of kyphosis; 27.8° preoperatively, 30.1° postoperatively, and then 44.5° at the follow-up. The other 3 patients didn't meet the criteria of failure, but showed only small degree of improvement; average 20.8°, 15.6°, and then 18.1°. They seems to be prone to failure, and more follow-up is required. In this study, the patients were divided into two groups; a group with screws on the injured vertebra and the other group without screws on the injured vertebra. The difference of kyphotic angle change between these two groups was evaluated (Table 3). The latter group showed poor initial correction as well as deterioration in the overall correction. According to this result, short-segment fixation not involving the injured vertebra itself is not firm enough and has high tendency to develop reduction failure, instrumentation failure, or progression of kyphosis. Therefore, if possible, not only the adjacent vertebrae but also the injured vertebra itself should be stabilized with instrumentation for firmer fixation. For inevitable cases due to severe destruction of injured vertebra, the authors recommend long-segment fixation covering two levels above and one level below the injured level, or one level above and two levels below, depending on the severity of upper or lower end-plate destruction.

Various studies on bone grafting have been performed, but there are still many controversies. Sanderson et al reported 20 cases of short-segment fixation without bone fusion, and they showed successful results even after routine removal of instrumentation at 6 to 12months postoperatively, concluding that bone grafting is not necessary[34]. They considered that sufficient bone and soft tissue healing would occur if the reduction was achieved soon after injury. Alanay et al also mentioned that bone grafting could not decrease the failure rate[2]. However, the majority of authors were in favor of bone grafting, and they used autogenous iliac bone most frequently. In this study, autogenous posterolateral bone grafting was performed in all cases. Bones from the laminae and the spinous processes which were removed after laminectomies were used instead of iliac bones, allografts, or artificial substitutes. Louis et al performed facet joint fusion using bones from the spinous processes and laminae in patients with thoracolumbar fractures[25]. Csecsei et al, Kai et al, and Miura et al reported successful interbody fusion using only laminectomy bones[9,21,29]. Hirunyachote et al reported 97.56% of successful posterolateral bone fusion using only laminae and spinous processes, and Kasai et al, by the same method, reported 82.8% of successful posterolateral fusion which was equivalent to other methods of grafting[19,22]. This procedure of bone fusion is free from foreign body infection from allografts or artificial substitutes, or donor site infection. It is convenient for the operators and comfortable for the patients due to not making another incision at doner site. The follow-up radiographs showed excellent bone fusion in all cases and no complications related to this procedure occurred (Fig. 3D).

Conclusion

Short-segment pedicular fixation and fusion is an efficient and safe method in the treatment of unstable thoracolumbar burst fracture. In this study, short-segment fixation brought improvement in kyphotic angle, vertebral height, and neurological status. With proper patient selection, adequate intraoperative reduction with screw fixation involving the

injured vertebra itself, and strict postoperative spinal bracing, the complications of short-segment fixation can be minimized.

References

1. Aebi M, Etter C, Kehl T, Thalgott J : Stabilization of the lower thoracic and lumbar spine with the internal spinal skeletal fixation system : Indications, techniques, and first results of treatment. **Spine 12** : 544-551, 1987
2. Alanay A, Acaroglu E, Yazici M, Oznur A, Surat A : Short-segment pedicle instrumentation of thoracolumbar burst fractures. **Spine 26** : 213-217, 2001
3. Alvine GF, Swain JM, Asher MA : The safety and efficacy of variable screw placement(VSP) and Isola spinal implant systems for the surgical treatment of thoracolumbar burst fractures. **J Bone Joint Surg 79B (Suppl)** : 306, 1997
4. Benzel EC, Larson SJ : Functional recovery after decompressive operation for thoracic and lumbar spine fractures. **Neurosurgery 19** : 772-778, 1986
5. Bradford DS, Akbarnia BA, Winter RB : Surgical stabilization of fractures and fracture-dislocations of the thoracic spine. **Spine 2** : 185-196, 1977
6. Cantor JB, Labwohl NH, Garvey T : Nonoperative management of stable thoracolumbar burst fractures with early ambulation and bracing. **Spine 18** : 971-976, 1993
7. Carl AL, Tromanhauser SG, Roger DJ : Pedicle screw instrumentation for thoracolumbar burst fractures and fracture-dislocations. **Spine 17** : 317-324, 1992
8. Chun SW, Hwang JH, Sung JK, Hwang SK, Hamm IS, Park YM, et al : Pedicle screw fixation and posterolateral fusion for thoracolumbar spine fracture. **J Korean Neurosurg Soc 28** : 644-648, 1999
9. Csecsei GI, Klekner AP, Dobai J, Lajgut A, Sikula J : Posterior interbody fusion using laminectomy bone and transpedicular screw fixation in the treatment of lumbar spondylolisthesis. **Surg Neurol 53** : 2-7, 2000
10. Daniaux H, Seykora P, Genelin A, Lang T, Kathrein A : Application of posterior plating and modifications in thoracolumbar spine injuries : Indications, techniques and results. **Spine 16** : 125-133, 1991
11. Devito DP, Tsahakis PJ : Cotrel-Dubousset instrumentation in traumatic spine injuries. **Proceedings of the Sixth International Congress on Cotrel-Dubousset Instrumentation.** Montpellier : Sauramps Medical, 1989, pp41-46
12. Dick W, Kluger P, Magerl F : A new device for internal fixation of thoracolumbar and lumbar spine fractures : the “Fixateur Interne”. **Paraplegia 23** : 225-232, 1985
13. Dickson JH, Harrington PR, Erwin WE : Results of reduction and stabilization of the severely fractured thoracic and lumbar spine. **J Bone Joint Surg 60A** : 799-805, 1978
14. Ebelke DK, Asher MA, Neff JR, Krake DP : Survivorship analysis of VSP spine instrumentation in the treatment of thoracolumbar and lumbar burst fractures. **Spine 16** : 428-492, 1991
15. Esses SI, Botsford DJ, Wright T, Bednar D, Bailey S : Operative treatment of spinal fractures with the AO internal fixator. **Spine 16** : S146-S150, 1991
16. Frankel H, Hancock DO, Hyslop G : The value of postural reduction in the initial management of closed injuries of the spine with paraplegia and tetraplegia. **Paraplegia 7** : 179-192, 1969
17. Gillet P, Meyer R, Fatemi F, Lemaire R : Short-segment internal fixation using CD instrumentation with pedicular screws : Biomechanical Testing. **Proceedings of the Sixth International Congress on Cotrel-Dubousset Instrumentation.** Montpellier : Sauramps Medical, 1989, pp19-24
18. Gurwitz GS, Dawson J, McNamara MJ : Biomechanical analysis of three surgical approaches for lumbar burst fractures using short segment instrumentation. **Spine 18** : 977-982, 1993
19. Hirunyachote P, Adulkasem W : Posterolateral fusion with autogenous laminospinous process bone graft. **J Med Assoc Thai 85** : 1105-1112, 2002
20. Holt BT, McCormack T, Gaines RW : Short segment fusion - anterior or posterior approach - The load-sharing classification of spine fractures. **Spine 7** : 189-197, 1993
21. Kai Y, Oyama M, Morooka M : Posterior lumbar interbody fusion using local facet joint autograft and pedicle screw fixation. **Spine 29** : 41-46, 2003
22. Kasai Y, Takegami K, Uchida A : Mixture ratios of local bone to artificial bone in lumbar posterolateral fusion. **J Spinal Disord Tech 16** : 31-37, 2003
23. Kramer DI, Rodgers WB, Mansfield FL : Transpedicular instrumentation and short-segment fusion of thoracolumbar fractures. **J Orthop Trauma 9** : 499-506, 1995
24. Lindsey RW, Dick W : The Fixateur Interne in reduction and stabilization of thoracolumbar spine fractures in patients with neurologic deficit. **Spine 16** : 140-145, 1991
25. Louis CA, Gauthier VY, Louis RP : Posterior approach with Louis plates for fractures of the thoracolumbar and lumbar spine with and without neurologic deficits. **Spine 23** : 2030-2039, 1998
26. McAfee PC, Yuan HA, Fredrickson BE, Lubicky JP : The value of computed tomography in thoracolumbar fractures. **J Bone Joint Surg 65A** : 641-473, 1983
27. McCormack T, Kariokovic E, Gaines RW : The load sharing classification of spine fractures. **Spine 19** : 1741-1744, 1994
28. McLain FR, Sparling E, Benson RD : Early failure of short-segment pedicle instrumentation for thoracolumbar burst fractures : A preliminary report. **J Bone Joint Surg 75A** : 162-167, 1993
29. Miura Y, Imagama S, Yoda M, Mitsuguchi H, Kachi H : Is local bone viable as a source of bone graft in posterior lumbar interbody fusion. **Spine 28** : 2386-2389, 2003
30. Mumford J, Weinstein JN, Spratt KF : Thoracolumbar burst fractures : The clinical efficacy and outcome of nonoperative management. **Spine 8** : 955-970, 1993
31. Parker JW, Lane JR, Karaikovic E, Gaines RW : Successful short-segment instrumentation and fusion for thoracolumbar spine fractures : A consecutive $4\frac{1}{2}$ year series. **Spine 25** : 1157-1169, 2000
32. Razak M, Mahmud MM, Hyzan MY, Omar A : Short segment posterior instrumentation, reduction and fusion of unstable thoracolumbar burst fractures - A review of 26 cases. **Med J Malaysia 55 (Suppl)** : 9-13, 2000
33. Roy-Camille R, Saillant G, Mazel C : Internal fixation of the lumbar spine with pedicle screw plating. **Clin Orthop 203** : 7-17, 1986
34. Sanderson PL, Fraser RD, Hall DJ, Cain CMJ, Osti OL, Potter GR : Short segment fixation of thoracolumbar burst fractures without fusion. **Eur Spine J 8** : 495-500, 1999
35. Sasso RC, Cotler HB : Posterior instrumentation and fusion for unstable fractures and fracture-dislocations of the thoracic and lumbar spine. **Spine 18** : 450-460, 1993
36. Sasso RC, Cotler HB, Reuben JD : Posterior fixation of thoracic and lumbar spine fractures using DC plates and screws. **Spine 16** : 134-139, 1981
37. Schnee CL, Ansell LV : Selection criteria and outcome of operative approaches for thoracolumbar burst fractures with and without neurological deficit. **J Neurosurg 86** : 48-55, 1997
38. Steffee AD, Biscup RS, Sitkowski DJ : Segmental spine plates with pedicle screw fixation : A new internal fixation device for disorders of the lumbar and thoracolumbar spine. **Clin Orthop 203** : 45-53, 1986
39. Willen JAG, Lindahl S, Nordwall A : Unstable thoracolumbar fracutres : A comparative study of conservative treatment and Harrington instrumentation. **Spine 10** : 111-122, 1985