Clinical Article

Pituitary Irradiation by Gamma Knife in Intractable Cancer Pain

Ki-Hun Kwon , M.D., Taek-Kyun Nam, M.D.,
Yong-Seok Im, Ph.D., Jung-Il Lee, M.D.

Department of Neurosurgery, Samsung Medical Center, Sungkyunkwan University School of Medicine, Seoul, Korea

Objective : Cancer pain has been treated by gamma knife radiosurgery(GKS), targeted to the pituitary gland-stalk, as an alternative new pain control method. The purpose of this study is to prove the efficacy and the safety of this treatment.

Methods : Seven patients with intractable cancer pain underwent pituitary gland-stalk irradiation by gamma knife. Selections for patient inclusion in this treatment protocol were no other effective pain treatment options, general condition rated as greater than 40 on Karnofsky Performance Scale, and pain relief by morphine though not satisfactory. The target was the junction between the pituitary stalk and the neurohypophysis. The maximum dose was 150~160Gy with one isocenter in 8mm collimator or two isocenters in 4mm collimator keeping the radiation dose to the optic nerve less than 8Gy.

Results : In all seven cases, the significant pain reduction was obtained during immediate post-GKS period without serious complications except one patient who developed transient hypopituitarism and diabetes insipidus. Pain relief was observed within several days, and this effect was prolonged for a quite long time. At a follow up of 1.5 to 13 months, pain recurred in two patients and no hormonal and visual dysfunctions were observed.

Conclusion : Despite insufficient experience, the efficacy and the safety of GKS for intractable cancer pain were demonstrated in seven patients. This treatment has the potential to ameliorate cancer pain, and GKS will play a more important role in the treatment of intractable pain.

KEY WORDS : Gamma knife radiosurgery · Pituitary irradiation · Intractable cancer pain.

Introduction

Approximately 38% of patients with cancer experience severe pain. Moreover, in the terminal stages, more than 60% of patients develop intractable pain[2,17,18]. Cancer-related pain can be intractable pain that is not relieved completely by any modalities such as focal irradiation, functional surgery, and medication[9]. This pain is too severe to allow patients to experience an acceptable quality of life.

Two or three decades ago, cancer pain had been treated by surgical or chemical hypophysectomy[3-6,10,12-15,22]. These treatments provided most patients with relief from their severe pain clinically. However, severe adverse effects including panhypopituitarism, diabetes insipidus, and visual dysfunction appeared in almost all of the cases. In patients with terminal disease, these complications were more significant than the pain relief and the procedure was almost discarded in routine clinical practice.

Gamma knife radiosurgery(GKS) has been widely used in the treatment of brain diseases, not only tumors and vascular malformations but also functional disorders such as epilepsy, movement disorders, and intractable pain, including cancer pain, which is hardly to be cured[8]. In 1968, Leksell[11] published the results of a centrum medianum gamma thalamotomy for cancer pain in two patients. Buckland et al.[1] tried to treat cancer pain using GKS to the pituitary gland with a dose of 200~250Gy. They first reported the accomplishment of pituitary ablation by GKS. We have also tried an alternative approach to surgical or chemical hypophysectomy by using GKS to induce a lesion in the stalk of the pituitary gland (maximum dose 150~160Gy).

Until now, only a few patients have been treated intractable cancer pain using GKS. However, the early results have been promising, and the significant side effects notably observed after chemical and surgical hypophysectomy have been absent. In this study, we prospectively evaluated the efficacy and the safety of pituitary irradiation by gamma knife.

• Received : June 7, 2004 • Accepted : June 21, 2004
• Address for reprints : Jung-Il Lee, M.D., Department of Neurosurgery, Samsung Medical Center, Sungkyunkwan University School of Medicine, 50 Ilwon-dong, Gangnam-gu, Seoul 135-710, Korea
Tel : 02)3410-3499, 3494, Fax : 02) 3410-0048
E-mail : jilee@smc.samsung.co.kr

Materials and Methods

The characteristics and eligibility of patients

From March 2003 to March 2004, seven patients suffering intractable pain due to cancer metastases were treated with pituitary gland-stalk irradiation using Leksell Gamma Knife. The three female and four male patients had a mean age of 53.9 years. They were diagnosed as metastatic cancer of which origin sites were lung, colon, stomach, and brain. Then they suffered from severe intractable pain due to cancer metastasis. The symptom duration until GKS was 2~42months (mean duration : 9.9months). Clinical findings of the patients were summarized in Table 1.

Patient eligibility for entry into the trial was no other effective pain treatment options, general condition rated as greater than 40 on Karnofsky Performance Scale(KPS), and pain relief by morphine though not satisfactory.

The pre- and post-GKS assessment of patients

The items of evaluation were the site of the primary tumor, the activity and distribution of the cancer (using tumor markers, sonography, bone scintigraphy, and whole-body CT and/or MR imaging), the severity of pain level as quantified by Visual Analogue Scale(VAS), the endocrinological study, the visual function analysis including visual acuity, visual field, and eye movements, and the brain MR imaging to determine the relationship between the pituitary gland/stalk and surrounding structures.

The technique of GKS

The Leksell frame was applied to the head, and then images for dose planning were obtained from MR imaging. The MR images were T_1- and T_2-weighted or 3D FSE 1-mm axial and coronal slices. The images were exported to Leksell Gamma Plan (Version 5.34) for dose planning. The target center was set at the junction between the neurohypophysis and the stalk. The maximum dose was 150~160Gy with one isocenter in 8mm collimator or two isocenters in 4mm collimator keeping the radiation dose to the optic nerve less than 8Gy (Table 2). The 50% isodose covered both the lower part of the pituitary stalk and upper portion of the pituitary gland. The gamma angle was adjusted to ensure that the upper margin of the 8Gy containing isodose ran parallel to the optic nerves (Fig. 1). In addition, a plugging technique was used to modify the shape of the 8Gy isodose line to reduce the dose delivered to the optic pathway.

Results

In all patients, severe intractable pain improved significantly (>50% pain reduction quantified by VAS) within a few days (mean duration : 4.1days) after GKS (Table 2). After the treatment, they took medicine such as morphine and/or NSAIDs with reduced dose (19.1% of pre-GKS morphine dose) or intermittent use according to requirement of the patients. This effect of GKS on pains was maintained as long as they lived, and no recurrence of severe pain similar or worse

Table 1. Summary of presenting symptoms and findings

Case	Age /Sex	Diagnosis	Metastases	Symptoms	Symptom duration until pituitary GKS* (months)	Previous history of chemotherapy/ GKS or cerebral radiotherapy**	Previous radiotherapy for pain trigger sites	Response to opioids
1	54/F	Colon cancer (Adenocarcinoma)	Liver, Lung, Bone	Back pain	3	(+) / (−)	(+)	(+)
2	56/M	Lung cancer (Adenocarcinoma)	Brain, Bone	Shoulder pain	4	(+) / (+)	(+)	(+)
3	41/M	Chordoid meningioma	CSF seeding, Spinal cord	Back pain	12	(−) / (+)	(+)	(+)
4	62/F	Gastric cancer (Adenocarcinoma)	Liver, CBD, Ureter, Peritoneal seeding	Abdominal pain	2	(+) / (−)	(−)	(+)
5	63/M	Lung cancer (Adenocarcinoma)	Brain, Soft tissue of neck	Neck pain	2	(+) / (+)	(−)	(+)
6	47/F	Lung cancer (Adenocarcinoma)	Brain, Bone	Back and flank pain	42	(+) / (+)	(+)	(+)
7	54/M	Lung cancer (Large cell neuroendocrine carcinoma)	Brain, Chest wall	Chest wall pain	4	(−) / (+)	(+)	(+)

*GKS : Gamma knife radiosurgery **Gamma knife radiosurgery or radiotherapy for metastatic brain lesions

than preoperative pain occurred. But two patients complained aggravation of their pain compared with immediate post-GKS state in 1month and 6months after GKS, respectively. They suffered from chordoid meningioma with CSF seeding and adenocarcinoma of lung with bone metastases. No patient suffered from hormonal dysfunction except one patient who had preexisting pituitary hypofunction and diabetes insipidus. No patient developed visual dysfunction, either. Six patients and their family were much satisfied with the results of the treatment and the other thought it to be of a little benefit to their severe cancer pain.

Illustrative case

This 56-year-old previously healthy man suffered from lung cancer and harbored brain and bone metastases. He exhibited 80% KPS score and no focal neurological abnormality. He underwent GKS on metastatic brain lesions and systemic chemotherapy was given. He had suffered extremely severe pain from the bone metastasis at his right shoulder for 4 months after initial diagnosis and local irradiation with conventional radiotherapy was given with an inadequate effect. Before gamma knife treatment for pain control, his VAS score was 9. He also took oral morphine sulfate 120mg/day and fentanyl patch (75mcg/hr) was applied, which was somewhat effective for pain relief though not satisfactory. Finally, he underwent pituitary irradiation using gamma knife with a maximum dose of 160Gy with one isocenter using the 8mm collimator.

On the next day, his pain began to decrease and daily requirement of morphine sulfate decreased to 30mg/day. By postoperative day 7, there was pain reduction more than a half of preoperative pain scale (Fig. 2). He has been followed for 13months after pituitary irradiation. The pain related to the bone metastasis did not recur, and his pain remained at tolerable level with intermittent oral medication. No abnormality in pituitary hormone secretion occurred, and visual function remained intact. There were, however, new metastatic brain lesions after 4months from pituitary irradiation by gamma knife. He underwent GKS on the brain metastases once again and still alive at the time of this writing.

Discussion

Several decades ago, attempts were made to control cancer pain with hypophysectomy. In 1953, Luft and Olivecrona[14] reported their first experience with surgical hypophysectomy to control pain in patients with breast cancer; these patients also suffered severe pain related to bone metastases. Undoubtedly, they aimed to suppress the activity of the hormonal cancer by hypophysectomy. A surprising effect of the operation was the complete relief of the pain from the bone metastases. Thereafter, surgical hypophysectomy was performed worldwide with variations in technique. Zervas[22] favored a radiofrequency coagulation, Hardy[5] used a transsphenoidal pituitary ablation, and Forrest, et al.[3] used radioactive implants. Subsequently, chemical hypophysectomy with alcohol injected directly into the pituitary gland was performed as an alternative less invasive treatment by Greco, et al.[4], Moricca[15], Lipton, et al.[12],

Table 2. Treatment and outcome of pituitary irradiation by gamma knife

Case	KPS*	Collimator size (mm)	Number of isocenter	Maximum dose (Gy)	The period until pain reduction more than 50%** (days)	Pre-GKS VAS	Post-*** GKS VAS	Pre-GKS medication (M equi./d)†	Post-GKS medication (M equi./d)	Complication	Follow up (months)
1	50	8	1	160	4	10	3	150	60	(−)	1.5 (Expired)
2	80	8	1	160	7	9	1	300	30, NSAIDs‡	(−)	13
3‖	50	4	2	150	2	8	2	60	NSAIDs	(−)	9 (Expired)
4	40	4	2	160	2	10	4	390	100	aggravate preexisting HP & DI§	1 (Expired)
5	50	8	1	160	3	8	4	180	30	(−)	3 (Expired)
6‖	60	4	2	150	3	8	3	120, NSAIDs	30	(−)	1.5
7	70	4	2	150	8	10	1	120	NSAIDs	(−)	1.5

*KPS : Karnofsky Performance Scale; **Quantified by Visual Analogue Scale (VAS); ***2 weeks after GKS; †M equi./d : Equianalgesic dose of morphine (mg)/day. Doses of oxycodone and Fentanyl patch were converted into equianalgesic dose of morphine by equianalgesic dose ratios[16]. ‡NSAIDs : Non-steroidal anti-inflammatory drugs; §HP & DI : hypopituitarism and diabetes insipidus; ‖Pain was aggravated at 6months and 1month after GKS, respectively. However, the severity of pain did not reach preoperative level and could be controlled with oral opioids

and Katz and Levin[10]. Overall 64.4% of patients became pain free in the 1101 reported cases : pain-free status in 70% of 334 cases treated with surgical hypophysectomy and 61.9% of 767 cases treated with chemical hypophysectomy[3-6,10,12-15,22]. There were, however, significant adverse effects in almost all cases after these procedures. Panhypopituitarism was observed in all cases. Diabetes insipidus was observed in half of the cases. Eye movement disorder, visual field defect, hypothalamic insult, and meningitis were also observed in some cases[7]. Thus, although almost all patients experienced substantial relief after surgical or chemical hypophysectomy, they developed significant complications at the same time. Consequently, hypophysectomy disappeared from the armamentarium of cancer pain treatments.

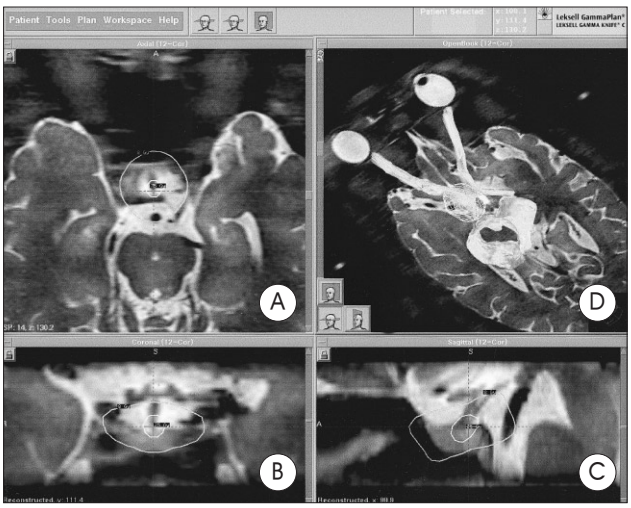

Fig. 1. Dose planning performed using Leksell Gamma Plan (Version 5.34). The figure shows the 50% isodose line (inner circle indicating 75Gy), and the anatomical relationship of structures around the target area including optic nerve, carotid artery, pituitary gland, stalk, and brainstem. The optic chiasm is located just out of 8Gy isodose line (outer large circle). A : Axial image; B : Coronal reconstructed image; C : Sagittal reconstructed image; D : 3D image superimposed on axial image showing the volume covered with 8Gy (mesh).

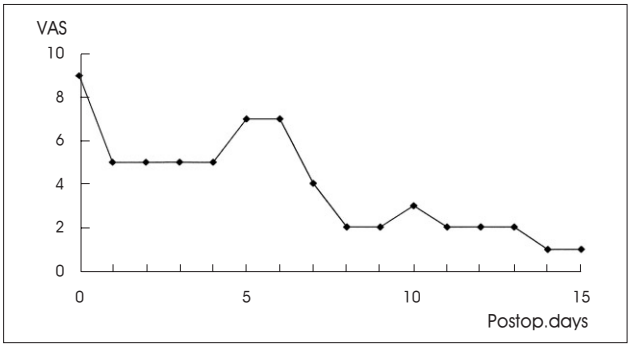

Fig. 2. (Case 2) Graph showing the change of Visual Analogue Scale after pituitary irradiation by gamma knife. By postoperative day 7, there is pain reduction more than a half of preoperative pain scale.

Gamma knife radiosurgery has also been applied to alleviate intractable pain. In 1968, Leksell performed thalamotomy using GKS in two patients with cancer pain; the centromedian nucleus was targeted with a dose of 200~250Gy maximally[11]. Steiner et al.[19] and Young et al.[20,21], also treated intractable pain in a similar way. In a clinical study by Young et al.[20,21], good response (>50% pain reduction) was observed in 65% of the patients. Buckland et al.[1] first tried to treat cancer pain using GKS to the pituitary gland with a dose of 200~250Gy. Recently, it was reputed that gamma hypophysectomy had surprisingly satisfactory clinical results with an early, complete, and prolonged clinical effect in control of cancer pain, and no important adverse effects[6,13].

The action mechanism of gamma hypophysectomy resulting in complete pain relief has not been elucidated yet. In the majority of patients with cancer pain, treatment with morphine resulted in pain reduction. Therefore, it was suspected that one action mechanism of gamma hypophysectomy might have triggered an intrinsic morphine-like effect[8]. β-Endorphin, whose precursor (pre pro-opiomelanocortin : PPOMC) was localized in the pituitary gland and the arcuate nucleus in the hypothalamus, is very well known to suppress this kind of severe pain similar morphine. In several reports, the level of β-endorphin increased after gamma hypophysectomy in both blood and cerebrospinal fluid of patients[8]. Hypophysectomy, ablation of the pituitary gland and stalk, was supposed to trigger the release of an excessive quantity of PPOMC into the blood and cerebrospinal fluid[8].

There are some reasons to suspect that gamma hypophysectomy may not initially trigger a destructive effect in the pituitary gland and stalk[7]. This is because there are a number of findings that could indicate a stimulating rather than a destructive effect : 1) there was no evidence of destructive changes, no dysfunction of endocrinological status, and no morphological changes on follow-up MR images; 2) clinical symptoms showed a stimulating effect on the hypothalamus with rapid recovery of appetite loss and general condition; and 3) MR spectroscopy revealed a stimulating effect in the hypothalamus with the level of N-acetyl aspartate, which is related to the activity of neurons, rising remarkably within 24hours after GKS[7].

According to our experiences, pituitary irradiation using gamma knife was also effective for the patients with not hormone-related cancer and no bone metastasis. These findings suggest that the initial mechanism of action may be different between surgical or chemical hypophysectomy and pituitary irradiation by gamma knife. Thus proper terminology for this procedure may be pituitary irradiation by gamma knife rather than hypophysectomy which suggests destructive mechanism.

Conclusion

Seven consecutive patients with cancer pain were treated by pituitary irradiation using gamma knife. All of seven patients experienced significant pain reduction within a short time and only one patient developed transient endocrine complication.

Until now, objective data is still limited and the exact therapeutic mechanism is unknown. However, the preliminary results suggest that this procedure has the potential to treat cancer pain. More clinical experiences and prospective studies are needed to establish the indication, technique, and mechanism of pituitary irradiation by gamma knife.

References

1. Buckland EO, Rahn T, Sarby B : Closed stereotaxic hypophysectomy by mean of ^{60}Co gamma radiation. **Acta Radiol Ther Phys Biol 11** : 545-555, 1972
2. Foley KM : The treatment of cancer pain. **N Engl J Med 313** : 84-95, 1985
3. Forrest APM, Blair DW, Peebles Brown AD : Radioactive implantation of the pituitary. **Br J Surg 47** : 61-70, 1959
4. Greco T, Sbaragli, Cammili L : L alcoolizatione della ipofisi per via transfenoidale nalla terapia di particoleri tumori maligni. **Settimana Med 45** : 355-356, 1957
5. Hardy J : Transsphenoidal hypophysectomy. **J Neurosurg 34** : 582-594, 1971
6. Hayashi M, Nakaya K, Ochiai T : Gamma knife radiosurgery for cancer pain-new trial method for gamma knife radiosurgical pituitary stalk ablation. **Stereotact Radiother (Jpn) 4** : 1-12, 2000
7. Hayashi M, Taira T, Chernov M, Fukuoka S, Liscak R, Yu CP, et al : Gamma knife surgery for cancer pain-pituitary gland-stalk ablation : a multicenter prospective protocol since 2002. **J Neurosurg (Suppl 5) 97** : 433-437, 2002
8. Hayashi M, Taira T, Chernov M, Izawa M, Liscak R, Yu CP, et al : Role of pituitary radiosurgery for the management of intractable pain and potential future applications. **Stereotact Funct Neurosurg 81** : 75-83, 2003
9. Jung JY, Chang JH, Chang JW, Park YG, Chung SS : Treatment of intractable cancer pain by stereotactic bilateral anterior cingulotomy. **J Korean Neurosurg Soc 30** : 456-462, 2001
10. Katz J, Levin AB : Treatment of diffuse metastatic cancer pain by instillation of alcohol into the sella turcica. **Anesthesiology 46** : 115-121, 1977
11. Leksell L : Cerebral radiosurgery I. Gamma thalamotomy in two cases of intractable pain. **Acta Chir Scand 134** : 585-595, 1968
12. Lipton S, Miles J, Williams N : Pituitary injection of alcohol for widespread cancer pain. **Pain 5** : 73-82, 1978
13. Liscak R, Vladyka V : Radiosurgical hypophysectomy in painful bone metastasis from breast cancer. **Cas Lek Ces 137** : 154-157, 1998
14. Luft R, Olivecrona H : Experiences with hypophysectomy. **J Neurosurg 10** : 301-316, 1953
15. Moricca G : Chemical hypophysectomy for cancer pain, in Bonica JJ (eds) : **Advances in Neurology 4, Pain**., New York : Raven Press, 1974, pp 707-714
16. Pereira J, Lawlor P, Vigano A, Dorgan M, Bruera E : Equianalgesic dose ratios for opioids : A critical review and proposals for long-term dosing. **J Pain Symptom Manage 22** : 672-687, 2001
17. Portnoy RK : Pain management in the older cancer patient. **Oncology 6** : S86-S98, 1992
18. Saunders DC : The philosophy of terminal care, in Saunders DC (eds) : **The Management of Terminal Malignant Disease**., London : Edward Arnold, 1984, pp 232-241
19. Steiner L, Forster D, Leksell L : Gamma thalamotomy in intractable pain. **Acta Neurochir (Wien) 52** : 173-184, 1980
20. Young RF, Jacques DS, Rand RW : Medial thalamotomy with the Leksell Gamma Knife for treatment of chronic pain. **Acta Neurochir Suppl (Wien) 62** : 105-110, 1994
21. Young RF, Jacques DS, Rand RW : Technique of stereotactic medial thalamotomy with the Leksell Gamma Knife for treatment of chronic pain. **Neurol Res 17** : 59-65, 1995
22. Zervas N : Stereotaxic radio-frequency surgery of the normal and abnormal pituitary gland. **Semin Med Beth Israel Hosp 280** : 429-437, 1969