

Case Report

A Case of Pial Arteriovenous Fistula with Giant Venous Aneurysm and Multiple Varices Treated with Coil Embolization

Hyuk-Jin Oh, M.D.,¹ Seok-Mann Yoon, M.D.,¹ Sung-Ho Kim, M.D.,² Jai-Joon Shim, M.D.¹

Department of Neurosurgery,¹ Soonchunhyang University Cheonan Hospital, Cheonan, Korea

Department of Neurosurgery,² Soonchunhyang University Gumi Hospital, Gumi, Korea

Intracranial pial arteriovenous fistulas (AVFs) are rare vascular lesions of the brain. These lesions consist of one or more arterial connection to a single venous channel without true intervening nidus. A 24-year-old woman visited to our hospital because of headache, vomiting, dizziness and memory disturbance that persisted for three days. She complained several times of drop attack because of sudden weakness on both leg. Cerebral angiograms demonstrated a giant venous aneurysm on right frontal lobe beyond the genu of corpus callosum, multiple varices on both frontal lobes fed by azygos anterior cerebral artery, and markedly dilated draining vein into superior sagittal sinus, suggesting single channel pial AVF with multiple varices. Transarterial coil embolization of giant aneurysm and fistulous portion resulted in complete disappearance of pial AVF without complication.

Key Words : Pial AVF · Giant venous aneurysm · Varices · Endovascular coils · Embolization.

INTRODUCTION

Intracranial pial arteriovenous fistulas (AVFs) are rare vascular lesions of the brain and account for 1.6% of all brain vascular malformations²⁾. They have been recently recognized as distinct vascular anomalies, different from brain arteriovenous malformations (AVMs)⁴⁾. These lesions differ from AVMs as they are direct artery to vein connections, have no nidus, and are composed of one or more direct arterial feeders with a single draining vein. Many of these have associated venous varix or giant venous aneurysm. They differ from dural AVFs as they acquire feeders from pial or cortical arteries and are not located within the leaflets of the dura^{2,9)}. We report a case of pial AVF with giant venous aneurysm and multiple varices on both frontal lobes across the midline, which was successfully treated with endovascular coil embolization.

CASE REPORT

A 24-year-old woman visited to our hospital because of head-

ache, vomiting, dizziness and memory disturbance that persisted for three days. She complained several times of drop attack because of sudden weakness on both leg. She had no history of hypertension, diabetes mellitus, seizures or head injury. She was alert and had no motor weakness. Brain computed tomography (CT) scans with contrast enhancement showed a large saccular and multiple irregular conglomerated enhancing lesions on both frontal lobes above the body of corpus callosum and anterior to the motor cortex. CT angiograms demonstrated a giant venous aneurysm on right frontal lobe and multiple varices on left frontal lobe, which were fed by azygos anterior cerebral artery (ACA). Brain magnetic resonance imaging showed irregular conglomerated signal void lesions on both frontal lobes, and large oval shaped signal void aneurysmal sac on right frontal lobe without mass effect (Fig. 1). On catheter angiography, there showed a giant venous aneurysm (30×20×25 mm in size) on right frontal lobe beyond the genu of corpus callosum. Sequential contrast filling of giant aneurysm on right frontal lobe from A4 branch of ACA (two small arteries merge together just before the fistula), left frontal large aneurysms, more smaller multiple engorged part of vein, and then markedly dilated draining vein into superior sagittal sinus, suggesting single channel pial AVF with multiple varices. Three dimensional rotational angiograms showed the feeding artery and giant aneurysm and other multiple venous aneurysms and varices clearly (Fig. 2).

Under the general anesthesia, a 6F Envoy guiding catheter

• Received : March 29, 2011 • Revised : May 4, 2011

• Accepted : August 30, 2011

• Address for reprints : Seok-Mann Yoon, M.D.

Department of Neurosurgery, Soonchunhyang University Cheonan Hospital,
8 Suncheonhyang 2-gil, Cheonan 330-721, Korea

Tel : +82-41-570-3649, Fax : +82-41-572-9297

E-mail : smyoon@sch.ac.kr

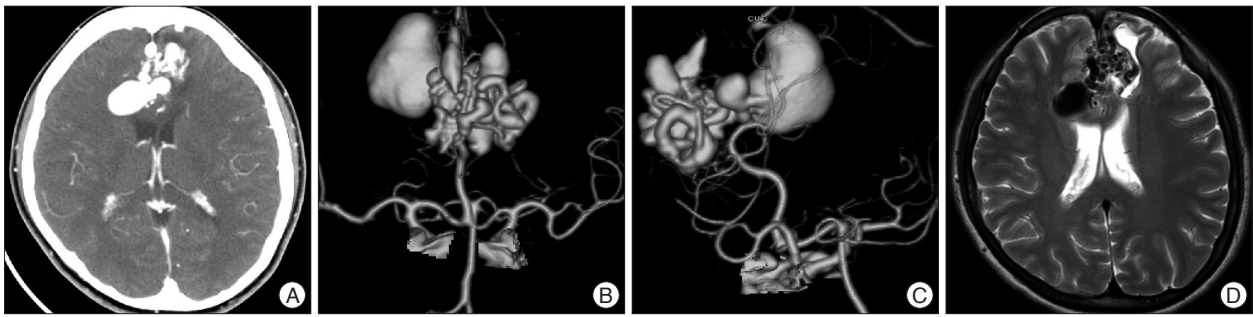


Fig. 1. Brain CT scan with contrast enhancement (A) showing saccular and irregular tubular contrast enhancement on both frontal lobes above the corpus callosum. CT angiogram (B and C) demonstrates giant aneurysm on right frontal lobe fed by azygos ACA and multiple conglomerated lesions on both frontal lobes across the midline suggesting venous varices. T2 weighted MR image (D) shows irregular conglomerated signal void lesions on both frontal lobes, and large oval shaped signal void aneurysmal sac on right frontal lobe without mass effect. CT : computed tomography, ACA : anterior cerebral artery, MR : magnetic resonance.

(Cordis, Miami, FL, USA) was placed on the right cervical internal carotid artery. Based on the 3-dimensional angiogram, working angle was determined. To confirm this diagnosis of pial AVF, balloon test occlusion was performed using 4×7 mm Hyperform balloon (EV3, Irvine, CA, USA). Test occlusion in distal ACA (pericallosal artery) beyond the genu of corpus callosum resulted in complete disappearance of all vascular lesions including giant aneurysm and varices, which meant single channel pial AVF (Fig. 3). Superselective angiogram at lateral projection showed giant aneurysm, multiple varices and dilated cortical vein clearly (Fig. 4A). Loose packing of giant aneurysm as a scaffold followed by tight packing of short fistulous portion was planned. Initial coil frame was made in the giant aneurysm under road-map guidance to occlude fistula (Fig. 4B). Loose packing of giant aneurysm using 15 coils followed by tight packing of the fistulous portion with small coil resulted in complete disappearance of pial AVF (Fig. 4C, D). She recovered well after the procedure and was discharged at postoperative 5 days without any complication. Follow up magnetic resonance angiography at 3 months showed suspicious filling of vascular sac on the left frontal lobe, necessitating catheter angiography (Fig. 4E).

DISCUSSION

Intracranial pial single-channel AVFs have recently been considered distinct from AVMs⁴⁾. They consist of one or more arterial connection to a single venous channel without true intervening nidus, unlike cerebral AVMs³⁾. They are rare cerebrovascular lesions, accounting for 1.6% of all lesions²⁾. The abnormality from AVFs arises from its high-flow nature. A fistulous communica-

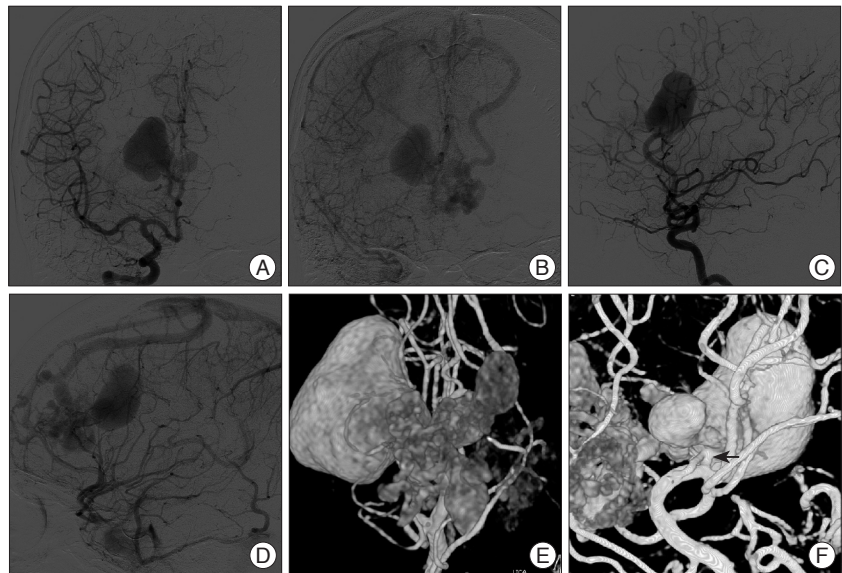


Fig. 2. Right ICA angiograms (A-D) and 3D angiograms (E and F) showing a giant venous aneurysm (30×20×25 mm) and multiple varices. Sequential visualization of giant aneurysm, large aneurysm, multiple varices and one marked dilated superficial veins are seen on early arterial phase (A and C) and delayed venous phase (B and D) of carotid angiograms. Feeding artery arising from the pericallosal artery beyond the corpus callosum, which appears as fenestration is evident on 3D angiograms (E and F). Fistulous portion seems to be on the just proximal to giant aneurysm (arrow). ICA : internal carotid artery.

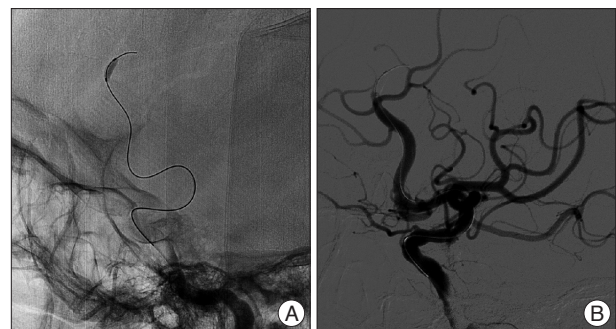


Fig. 3. Balloon test occlusion on the distal ACA (pericallosal artery) to confirm the feeders of pial AVF (A). Cerebral angiogram after balloon inflation (B) demonstrates complete disappearance of all vascular lesions including giant aneurysm, multiple varices and dilated draining vein into SSS. ACA : anterior cerebral artery, AVF : arteriovenous fistula, SSS : superior sagittal sinus.

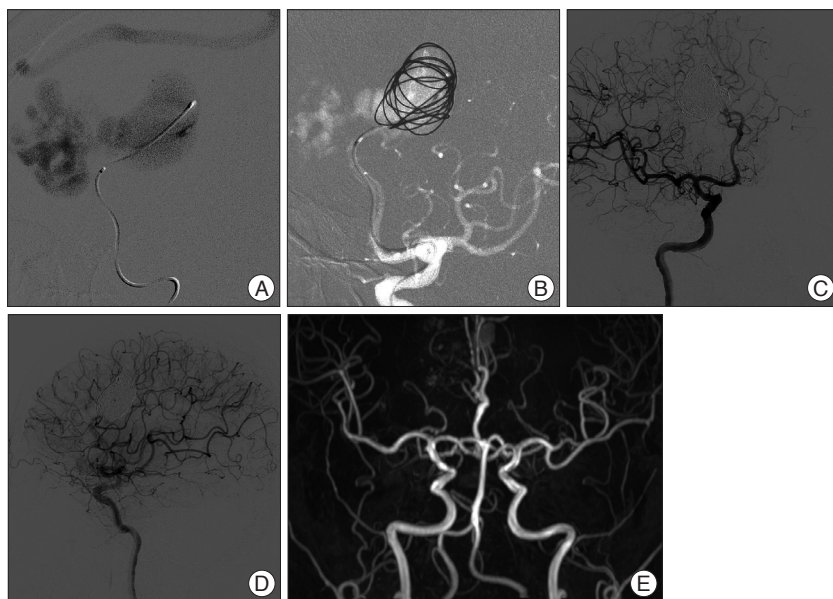


Fig. 4. Intraoperative (A and B) and postoperative (C and D) angiograms. Superselective angiogram at lateral projection (A) shows giant aneurysm, multiple varices and dilated cortical vein. Initial coil frame is made in the giant aneurysm under roadmap guidance (B) to occlude fistula. Loose packing of giant aneurysm using 15 coils followed by tight packing of the fistulous portion with smaller coil resulted in complete disappearance of pial AVF (C and D). Follow up MRA (E) at 3 months shows suspicious filling of vascular sac on the left frontal lobe, necessitating catheter angiography. AVF : arteriovenous fistula, MRA : magnetic resonance angiography.

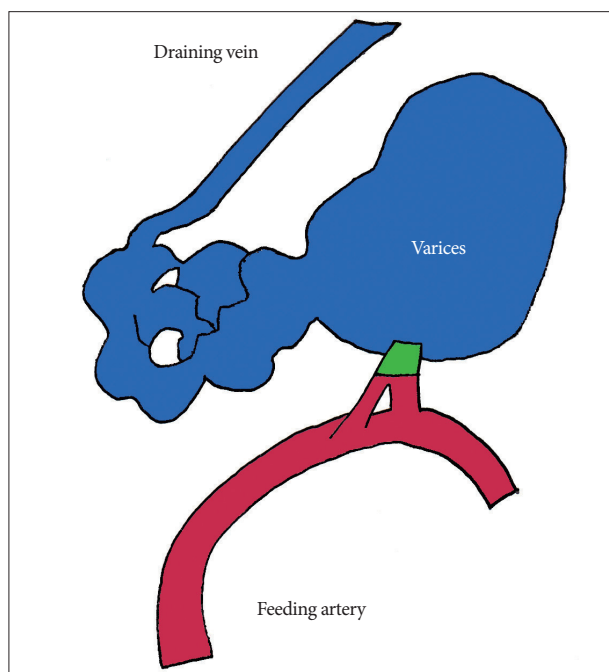


Fig. 5. Schematic drawing of pial AVF composed of double feeders originating from pericallosal artery (A4 ACA), varices, and single draining vein. Probable fistulous portion is marked with green color. AVF : arteriovenous fistula, ACA : anterior cerebral artery.

tion between feeding artery and single draining vein can produce venous dilatation, varix and even aneurysms by turbulent high flow^{3,5,10}.

Pial AVFs can result from trauma or may be congenital^{2,9}.

Congenital AVFs are usually diagnosed during infancy or early childhood, although many patients in the literature are young adult like this case³. The pathophysiologic mechanisms giving rise to these lesions are still not clear⁸. Hoh et al.³ postulated that a misstep in embryological development of the cerebrovasculature could produce these lesions. Alternatively, abnormal angiogenesis and associated vascular growth factors and cytokine may play a role.

Pial AVFs can cause seizures, hemorrhage, headache, neurological deficit, symptoms of increased intracranial pressure and intracranial bruit^{3,8}. In this case, she presented with headache, vomiting and drop attacks, which might be caused by ischemia on medial frontal lobes due to the steal of azygos ACA flow to pial AVF.

Pial AVFs can be diagnosed with cerebral angiography, especially 3D angiograms. Three dimensional angio-

grams can delineate complex angioarchitecture well because of its inherent capability of obtaining reconstruction images at any angles. In this case, the feeder from the azygos ACA (A4) was visualized clearly on 3D rotational angiogram.

Treatment strategies of pial AVFs are different than that of cerebral AVMs. Simple disconnection of arteriovenous shunting is considered enough in most cases, either by microsurgery or endovascular embolization without resection of entire vascular malformation³. This strategy is based on the characteristics of pial AVFs, which are high-flow nature of communication between an arterial feeder and a single draining vein without an intervening tangle of vessels. After establishment of arteriovenous connection, associated venous varices can be produced by high, turbulent flow caused by arteriovenous shunting^{6,8}. Thus, removal of varix was not necessary unless the malformation accompanied hematoma with mass effect.

In our case, single channel AVF fed by azygos ACA was confirmed by balloon occlusion test. Thus, the treatment was focused on the disconnection of single feeder from giant venous aneurysm, which was the most proximal part of venous varices (Fig. 5). Either microsurgery or endovascular embolization was considered possible to disconnect the fistula. But, we selected endovascular embolization rather than microsurgery, which may carry increased risk of neurologic morbidity, because the location of medial frontal region was relatively deep and fistulous portion could be accessed beyond the tortuous engorged varices.

Several embolic materials such as balloons, coils, glue and onyx can be used to disconnect the pial AVFs⁸. Of these, detachable coils have some advantages in the treatment of intra-

cranial high-flow AVFs because they are controllable before detachment. Migration of embolic materials to the distal draining vein can be prevented when we employ them^{1,7)}.

In our case, detachable coils were used to disconnect the AVF. Simple disconnection of fistulous portion only was not possible because the length of fistulous portion was too short to accommodate coils with stable condition. Therefore, partial filling of giant aneurysm followed by tight packing of fistulous portion resulted in successful obliteration of pial AVF in our case.

CONCLUSION

The authors report a rare case of pial AVF with giant venous aneurysm and multiple varices on the both frontal lobes fed by azygos ACA and drained into superior sagittal sinus through single left frontal superficial cortical vein. The pial AVF was treated with endovascular coils successfully without complication.

References

1. Andreou A, Ioannidis I, Nasir N : Transarterial balloon-assisted glue embolization of high-flow arteriovenous fistulas. *Neuroradiology* 50 : 267-272, 2008
2. Halbach VV, Higashida RT, Hieshima GB, Hardin CW, Dowd CF, Barnwell SL : Transarterial occlusion of solitary intracerebral arteriovenous fistulas. *AJNR Am J Neuroradiol* 10 : 747-752, 1989
3. Hoh BL, Putman CM, Budzik RF, Ogilvy CS : Surgical and endovascular flow disconnection of intracranial pial single-channel arteriovenous fistulae. *Neurosurgery* 49 : 1351-1363; discussion 1363-1364, 2001
4. Lasjaunias P, Manelfe C, Chiu M : Angiographic architecture of intracranial vascular malformations and fistulas--pretherapeutic aspects. *Neurosurg Rev* 9 : 253-263, 1986
5. Lawton MT, Jacobowitz R, Spetzler RF : Redefined role of angiogenesis in the pathogenesis of dural arteriovenous malformations. *J Neurosurg* 87 : 267-274, 1997
6. Lee JY, Son YJ, Kim JE : Intracranial pial arteriovenous fistulas. *J Korean Neurosurg Soc* 44 : 101-104, 2008
7. Luo CB, Teng MM, Chang FC, Chang CY : Endovascular treatment of intracranial high-flow arteriovenous fistulas by Guglielmi detachable coils. *J Chin Med Assoc* 69 : 80-85, 2006
8. Lv X, Li Y, Jiang C, Wu Z : Endovascular treatment of brain arteriovenous fistulas. *AJNR Am J Neuroradiol* 30 : 851-856, 2009
9. Santosh C, Teasdale E, Molyneux A : Spontaneous closure of an intracranial middle cerebral arteriovenous fistula. *Neuroradiology* 33 : 65-66, 1991
10. Viñuela F, Drake CG, Fox AJ, Pelz DM : Giant intracranial varices secondary to high-flow arteriovenous fistulae. *J Neurosurg* 66 : 198-203, 1987