online © ML Comm
www.jkns.or.kr 10.3340/jkns.2011.49.2.116
Print ISSN 2005-3711 On-line ISSN 1598-7876
J Korean Neurosurg Soc 49 : 116-119, 2011

Case Report

Endovascular Treatment of Blood Blister-Like Aneurysms Using Multiple Self-Expanding Stents

Young Woo Kim, M.D., Ik Seong Park, M.D., Min Woo Baik, M.D., Kwang Wook Jo, M.D.
Department of Neurosurgery, St. Mary's Hospital, College of Medicine, The Catholic University of Korea, Bucheon, Korea

The surgical as well as endovascular treatment of blood-blister-like aneursysms (BBAs) is extremely difficult because of these pathological natures, such as small and the fragile necks. The optimal treatment of BBAs has remained uncertain. Stents are known to divert blood flow and induce thrombosis of intracranial aneurysms. We report 3 cases of successful obliteration of BBAs after multiple stents placement.

Key Words : Blood-Blister-like Aneurysms · Neuroform Stent · Endovascular Treatment.

INTRODUCTION

Blood blister-like aneurysms (BBAs) are broad-based and located at the non-branching sites of the supraclinoid internal carotid artery (ICA)[10]. They are also known as ICA dorsal wall aneurysms. The optimal treatment of BBAs remains to be determined. The results of surgical treatment of BBAs have been reported to be poor, with high incidence of intraoperative rupture and postoperative rebleeding[1,6,9]. Endovascular techniques have been introduced as alternative treatment methods[8]. Several recent reports indicate that self-expanding stents like the dedicated intracranial stent may similarly remodel the blood flow and induce thrombosis in small pseudoaneurysms that are refractory to coil embolization[2,4]. We treated 3 patients with BBAs by the endovascular placement of multiple overlapping, self-expanding, neuroform stents without ICA trapping.

CASE REPORT

Case 1

A 47-year-old woman presented with sudden, severe headache. Computerized tomography (CT) revealed diffuse subarachnoid hemorrhage (Fig. 1A). However, no aneurysm was detected on computerized tomographic angiography (CTA) (Fig. 1B). Digital subtraction angiography (DSA) and CTA performed 6 days after the ictus revealed a BBA originating from the right distal ICA (Fig. 2). We performed the balloon test occlusion (BTO). However, the patient did not tolerate the BTO. Therefore, we recommended surgical treatment such as clip-

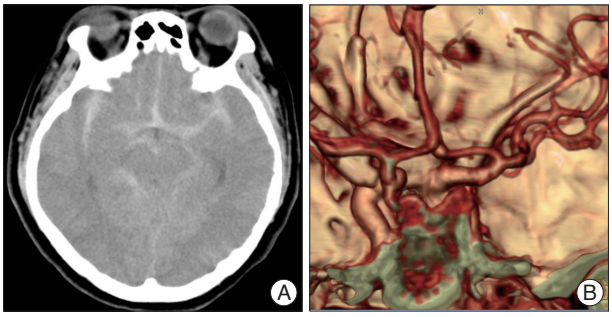

Fig. 1. Initial computed tomography and computed tomographic angiography images show diffuse subarachnoid hemorrhage (A) and no definite saccular aneurysm (B).

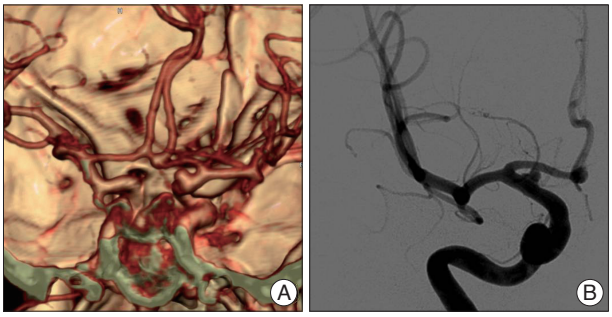

Fig. 2. Digital subtraction angiography (A) and computed tomographic angiography (B) images are obtained 6 days after admission. These images show a blood-blister-like aneurysm on the distal portion of the right internal carotid artery.

• Received : March 15, 2010 • Revised : May 19, 2010
• Accepted : January 13, 2011
• Address for reprints : Kwang Wook Jo, M.D.
Department of Neurosurgery, St. Mary's Hospital, College of Medicine, The Catholic University of Korea, 2 Sosa-dong, Bucheon 420-717, Korea
Tel : +82-32-340-2259, Fax : +82-32-340-7391
E-mail : jkw94@naver.com

ping, wrapping, and ICA trapping after bypass surgery; however, the patient refused to undergo surgical treatment. So, we decided endovascular treatment 9 days after the ictus. Antiplatelet medication was not given before the procedure. A 6F guiding catheter (Envoy MPC 90 Cordis; Johnson and Johnson Medical, Miami Lakes, FL, USA) was introduced into the ICA via the common carotid artery. A Neuroform stent (4.5×20 mm; Boston Scientific/Target, Fremont, CA, USA) was placed across the aneurysm. An additional Neuroform stent (4.5×15 mm) was then introduced and positioned such that it overlapped the previous stent for remodeling the blood flow into aneurysm. The blood flow was assessed by performing DSA immediately after the placement of the stents, and the obtained images showed reduced dye stasis within the aneurysm. Immediately after completion of the procedure, antiplatelet therapy with aspirin (100 mg/day) was initiated. In DSA images obtained 1 and 3 months after reconstruction, the BBA was visualized, but its neck appeared to have narrowed slightly; dye stasis within the aneurysm was also noted in the DSA image obtained at the capillary phase. (Fig. 3) With a view to further reducing the blood flow into the BBA, a 3rd stent (4.5×15 mm; Boston Scientific/Target) was implanted 3months after 1st reconstruction, overlapping the first 2 stents. DSA obtained 13 months after the placement of the 3rd stent confirmed the complete obliteration of the aneurysm (Fig. 4).

Case 2

A 42-year-old man presented with sudden, bursting headache. An initial CT showed diffuse SAH in the basal cistern and acute hydrocephalus (Fig. 5A). However, aneurysm was not detected in any of CTA or DSA images (Fig. 5B). External ventricular drainage was performed as the first treatment measure. Follow-up DSA was performed on the next day, which revealed the presence of a BBA on the distal portion of the distal ICA (Fig. 5C). Antiplatelet medication was not given before the procedure. Endovascular treatment was administered, with the placement of 2 overlapping Neuroform stents (3.5×15 mm and 4×20 mm; Boston Scientific/Target). Immediately after completion of the procedure, antiplatelet therapy with aspirin (100 mg/day) was initiated. A follow-up DSA image obtained 3 months after stent placement showed complete obliteration of the aneurysm (Fig. 5D).

Case 3

A 55-year-old man presented with a sudden headache. CT showed diffuse SAH in the basal cistern (Hunt and Hess grade II) (Fig. 6A). DSA showed a BBA in the ventral wall of the distal potion of the right ICA (Fig. 6B). Antiplatelet medication was not given before the procedure. Emergent endovascular treatment was administered, with placement of 2 Neuroform stents (4.5×20 mm and 4.5×15 mm; Boston Scientific/Target). Immediately after completion of the procedure, antiplatelet therapy with aspirin (100 mg/day) was initiated. A follow-up DSA image obtained 6 months after the placement of the stent showed remnant aneurysmal filling. However, enlargement or rupture of the aneurysm was not detected. Follow-up DSA performed 12 months after the stent placement showed complete obliteration (Fig. 6C).

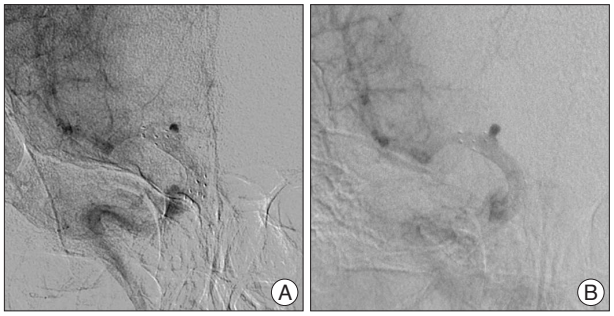

Fig. 3. Digial subtraction angiography images obtained 1month (A) and 3 months (B) after the reconstruction. Both images show dye stasis within the aneurysm in the capillary phase.

Fig. 4. A digial subtraction angiography image obtained 13 months after the placement of the third stent confirmed complete obliteration of the aneurysm.

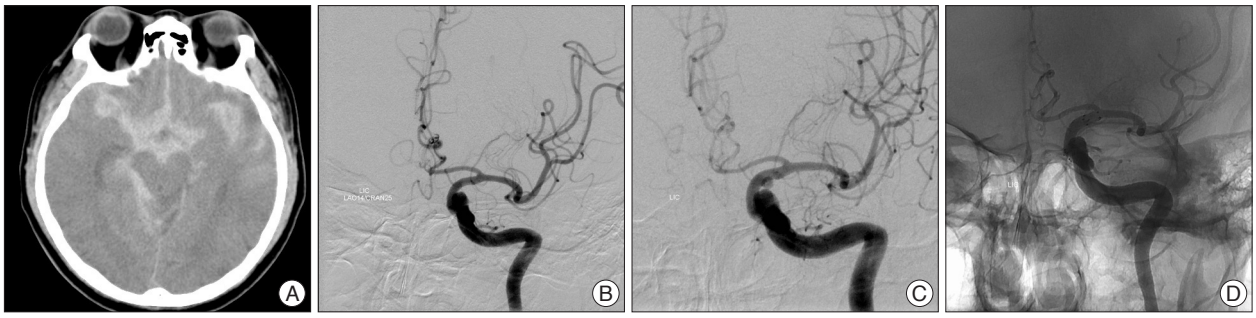

Fig. 5. Initial computed tomography and digial subtraction angiography (DSA) image show diffuse subarachnoid hemorrhage in the basal cistern (A) and no definite saccular aneurysm (B). Follow-up DSA on the next at after ictus reveal a blood-blister-like aneurysm on the distal portion of the right internal carotid artery (C). A DSA image obtained 3 months after stent placement shows complete obliteration of the aneurysm (D).

DISCUSSION

BBAs are an atypical type of ruptured aneurysm that usually appears as a small, hemispherical bulge or irregular bleb at the nonbranching sites of the supraclinoid portion of the ICA1). The available treatment options for BBAs are surgical or endovascular treatment. Various surgical and endovascular procedures such as clipping or wrapping, and surgical and endovascular ICA trapping and balloon or stent assisted coil embolization have been proposed[1,3,5,7-9]. The treatment of choice of BBAs is debatable .

In surgical treatment, BBAs are extremely dangerous lesions that often rupture during or after surgery. Sim et al.[11] reported a high incidence (50%) of premature rupture in cases treated by surgery than those treated by endovascular methods.

Also, BBAs have been treated with endovascular coil embolization alone[3,5]. Because the wall of the BBAs are very fragile and thin, only coil embolization may have potential associated risks of either aneurysm neck disruption or distal coil migration and be associated with a subsequent increase in the size of the aneurysm after the procedure.

Pathogenesis of BBAs is unknown. Several scientists consider BBA to be a specific type of dissecting aneurysm or pseudoaneurysm and that the main therapeutic target should be the affected arterial wall and not the BBA sac[4]. Considering this viewpoint, trapping should be the treatment of choice. However surgical and endovascular ICA trapping cannot be universally applied for all patients with BBAs; it is definitively contraindicated in patients who are unable to tolerate the BTO[8]. Thus, we need other alternative treatment methods.

Several recent literatures reported the treatment of BBAs using multiple stent by remodel the blood flow and induce thrombosis. Lee et al.[4] reported successful outcome in the treatment of BBAs by reconstructive methods such as the placement of covered stent, stent-assisted coil embolization and stent-assisted coil embolization with stent in stent method. The covered-stent method has many limitations such as insufficient collateral flow or close anterior choroidal artery. Furthermore, the placement of covered stents into ICA's tortuous cavernous portion is technically difficult because of their stiffness. Furthermore, this method also may not be completely safe from rebleeding during the procedure. Also, sufficient collateral supply on preoperative angiographic evaluation cannot always protect the patient from postoperative ischemic complication. In this study on three patients who underwent covered stent placement, one patient died of ICA rupture during the procedure. Other 3 patients who received stent-assisted coil alone showed BBA regrowth on short-term follow-up angiography but without rebleeding. Two of the 3 recurrent BBAs were re-treated by coiling followed by a second overlapping stent insertion. Imaging studies of above 2 patients revealed a radiolucent gap between the coil mass and the ICA lumen, which may be presumed as representative of neointima formation. However, all 3 patients who received stent assisted coil with stent-within-stent technique showed complete remission of BBA. Also, the stent-in-stent method is technically simpler than the covered-stent method and allows preservation of some collateral vessels such as the anterior choroidal artery. Follow-up DSAs were available for all 9 patients with BBAs (3-24 months; average, 6.7 months). In eight cases, complete obliterations of BBAs were achieved

Fiorella et al.[2] recently published a report on 10 cases of intracranial pseudoaneurysms, including 2 cases of BBAs, one of which was treated with the placement of a single Neuroform stent and the other, with the placement of 3 overlapping Neuroform stents; complete resolution of the BBA was achieved in both cases. Follow-up DSAs were available for all 10 patients with pseudoaneurysms (1-18.5 months; average, 9.0 monhs). In nine cases, the aneurysms were complete and near complete resolution. Our results are consistent with those of Fiorella et al. Overlapping double stents may double the strut density and thickness of the stent density and that of the stent, thus reinforcing blood-flow remodeling and arterial wall support. These effects may help reconstruct the fragile neck of the BBA and prevent its regrowth. Furthermore, a greater strut density and stent thickness promotes more neointima formation[4].

In all our cases, complete obliteration of the BBAs was achieved with the application of only the stent-within-stent method, as evident in follow-up imaging studies (3-13 mo; average, 9.3

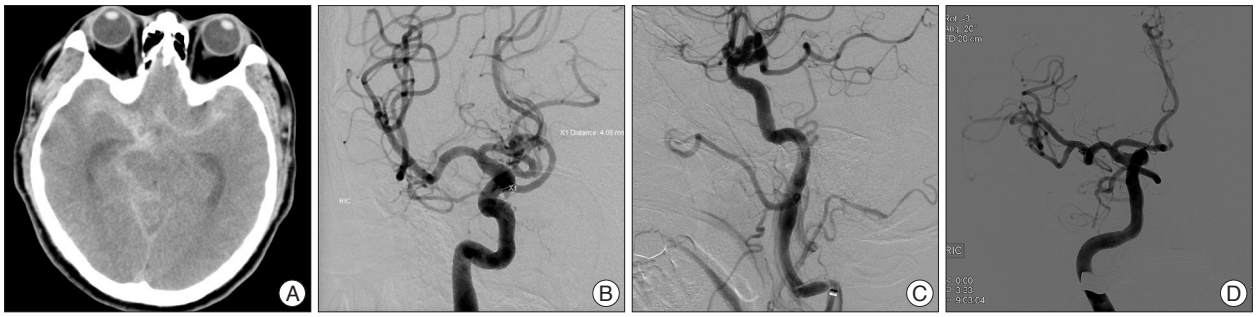

Fig. 6. Initial computed tomography and digial subtraction angiography (DSA) image show diffuse subarachnoid hemorrhage in the basal cistern (A) and a BBA in the ventral wall of the distal potion of the right internal carotid artery (B). Follow-up DSAs image obtained 6month (C) and 12 months (D) after the reconstruction. The first follow-up image shows remnant aneurysmal filling (C). The last follow-up image obtained 12 months after stent placement shows complete obliteration of the aneurysm (D).

mo). These results also were confirmed with previous reports[2].

Above results of previous reports including our cases[2,4] show that immediate complete obliteration of BBAs is not accomplished. Neverthless, incomplete obliteration of BBAs in acute stage may cause rebleeding, although rebleeding did not occur including our cases. However, it takes a long time to have BBAs to be completely obliterated. Above results of previous reports[2,4] including our cases show that stent-within-stent procedure significantly achieved the healing membrane that formed across the aneurysm neck by remodeling the blood flow and induced thrombosis and subsequent neointimal endothelial formation from 6 to 9 months after procedure. At the same time, periprocedural anticoagulation and antiplatelet therapy were required in cases of stent replacement for prevention of thromboembolic event. We began antiplatelet therapy with aspirin (100 mg/day) immediately after completion of the procedure because we worried about rebleeding. Although Fiorella et al.[2] pretreated with nonenteric coated aspirin (325 mg) and clopidogrel (75 mg) for a minimum of four days before the procedure, periprocedural rebleeding did not occur.

The cases of BBAs in which even surgical and endovascular trapping, and stent-assisted coil deployment are impossible, multiple stent-trapping methods would be considered and these methods may provide good outcome in difficult cases.

CONCLUSION

In the present 3 cases, the ruptured BBAs were successfully treated by endovascular treatment. Multiple stents placement may be a viable option in BBAs that are not amenable to open surgical treatment or endovascular coil embolization.

References

1. Abe M, Tabuchi K, Yokoyama H, Uchino A : Blood blister like aneurysms of the internal carotid artery. **J Neurosurg 89** : 419-424, 1998
2. Fiorella D, Albuquerque FC, Deshmukh VR, Woo HH, Rasmussen PA, Masaryk TJ, et al. : Endovascular reconstruction with the Neuroform stent as monotherapy for the treatment of uncoilable intradural pseudoaneurysms. **Neurosurgery 59** : 291-300; discussion 291-300, 2006
3. Kim BM, Chung EC, Park SI, Choi CS, Won YS : Treatment of blood blister-like aneurysm of the internal carotid artery with stent-assisted coil embolization followed by stent-within-a-stent technique. Case report. **J Neurosurg 107** : 1211-1213, 2007
4. Lee BH, Kim BM, Park MS, Park SI, Chung EC, Suh SH, et al. : Reconstructive endovascular treatment of ruptured blood blister-like aneurysms of the internal carotid artery. **J Neurosurg 110** : 431-436, 2009
5. McNeely PD, Clarke DB, Baxter B, Vandorpe RA, Mendez I : Endovascular treatment of a "blister-like" aneurysm of the internal carotid artery. **Can J Neurol Sci 27** : 247-250, 2000
6. Meling TR, Sorteberg A, Bakke SJ, Slettebo H, Hernesniemi J, Sorteberg W : Blood blister-like aneurysms of the internal carotid artery trunk causing subarachnoid hemorrhage: treatment and outcome. **J Neurosurg 108** : 662-671, 2008
7. Ogawa A, Suzuki M, Ogasawara K : Aneurysms at nonbranching sites in the surpaclinoid portion of the internal carotid artery: internal carotid artery trunk aneurysms. **Neurosurgery 47** : 578-583; discussion 583-586, 2000
8. Park JH, Park IS, Han DH, Kim SH, Oh CW, Kim JE, et al. : Endovascular treatment of blood blister-like aneurysms of the internal carotid artery. **J Neurosurg 106** : 812-819, 2007
9. Redekop GJ, Woodhurst B: Unusual aneurysms of the distal internal carotid artery. **Can J Neurol Sci 25** : 202-208, 1998
10. Satoh A, Nakamura H, Odaki M, Kobayashi S, Kageyama Y, Fukuda K, et al. : High risk aneurysms of the internal carotid artery : dorsal IC aneurysm. **Surg Cereb Stroke 21** : 467-472, 1993
11. Sim SY, Shin YS, Cho KG, Kim SY, Kim SH, Ahn YH, et al. : Blood blister-like aneurysms at nonbranching sites of the internal carotid artery. **J Neurosurg 105** : 400-405, 2006