KISEP

CLINICAL ARTICLE

J Korean Neurosurg Soc 41 : 161-165, 2007

Vertebroplasty Utilizing Percutaneous Vertebral Body Access (PVBA) Technique for Osteoporotic Vertebral Compression Fractures in the Middle Thoracic Vertebrae

Yong-Jun Cho, M.D., Jong-Hun Choi, M.D., Sung-Min Cho, M.D.

Department of Neurosurgery, Chunchon Sacred Heart Hospital, College of Medicine, Hallym University, Chuncheon, Korea

Objective : Percutaneous approach to the middle thoracic vertebra through the transpedicular route for the patients with osteoporotic vertebral compression fractures is difficult due to the small size of the pedicle and parasagittally oriented vertebral body anatomy. The percutaneous vertebral body access (PVBA) technique utilizing the posterolateral extrapedicular approach avoids the pedicle and provides direct access to the vertebral body. The objective of this study is to evaluate the efficacy of the vertebroplasty utilizing PVBA technique for osteoporotic vertebral compression fractures in the middle thoracic vertebrae.

Methods : A retrospective review was done on 20 patients who underwent vertebroplasty utilizing PVBA technique performed for painful osteoporotic compression fracture in the middle thoracic vertebrae at 22 levels from May 2003 to June 2006. The average amount of the injected cement was 1.5-2.5ml. The postprocedural outcome was assessed using a visual analogue scale (VAS).

Results : The treated vertebrae were T5 (1 level), T6 (5 levels), T7 (7 levels), and T8 (9 levels). The compression rate and kyphotic angle were improved after procedure from 18%±13.4 to 16%±13.8 ($p > 0.05$) and from 6.9°±6.7 to 6.6°±6.2 ($p > 0.05$), respectively. Preprocedural VAS was 8.2±0.70 and was decreased to 2.1±1.02 ($p < 0.01$) after treatment. Postprocedural cement leakage was noted in 3 levels (13.7%). There were no cases of leakage to epidural space or neural foramen, segmental artery injury, and pneumothorax.

Conclusion : These results suggest that the complication rates are low and good results can be achieved with vertebroplasty utilizing PVBA technique for the osteoporotic vertebral compression fractures especially in the middle thoracic vertebrae.

KEY WORDS : Vertebroplasty · Osteoporosis · Spinal fractures · Middle thoracic vertebrae.

Introduction

Percutaneous vertebroplasty has been reported to alleviate pain and to prevent further collapse in patients with vertebral compression fractures[2,3,5,6,10,15,16,24]. Some clinicians, however, have declined to use the procedure by the transpedicular approach in patients with osteoporotic vertebral compression fracture(s) in the middle thoracic vertebrae (from T5 to T8), because the middle thoracic pedicles are smaller and more parasagittally oriented and thus do not readily facilitate needle entry through the pedicle[26].

Percutaneous vertebral body access (PVBA) technique through the posterolateral extrapedicular approach was recently developed to facilitate needle insert to the vertebral body regardless of the size of the pedicles. The posterolateral extrapedicular approach avoids the pedicle and provides direct access to the anterior vertebral body, therefore it can easily gain access to the target area of the fractured vertebrae even in the middle thoracic vertebra while avoiding the spinal canal and pleural space.

The purpose of this study is to assess the effectiveness and safety of percutaneous vertebroplasty utilizing posterolateral extrapedicular PVBA technique using polymethylmethacrylate (PMMA) for patients with painful vertebral compression fracture in the middle thoracic vertebrae.

• Received : October 26, 2006 • Accepted : January 5, 2007
• Address for reprints : Yong-Jun Cho, M.D., Department of Neurosurgery, Chunchon Sacred Heart Hospital, College of Medicine, Hallym University, 153 Gyo-dong, Chuncheon 200-704, Korea Tel : +82-33-240-5173, Fax : +82-33-242-9970, E-mail : nssur771@hanmail.net

Materials and Methods

From May 2003 to June 2006, twenty patients with osteoporotic compression fractures at 22 levels in middle thoracic vertebrae underwent percutaneous extrapedicular vertebroplasty utilizing posterolateral PVBA technique. We retrospectively analysed the radiographic and functional outcome in these patients. Eighteen patients had 1 vertebra injected and 2 patients had 2 vertebrae (T7 and T8) injected.

Eligibility criteria included refractory pain to conservative therapy (rest, activity modification, analgesics, and physical therapy) and densitometric evidence of osteopenia or osteoporosis, and acute fracture activity on magnetic resonance imaging (MRI) and technetium^{99m} bone scan. Patients were excluded if they had impaired coagulopathy, osteomyelitis, retropulsion of bony fragments into the spinal canal, and pathologic fracture due to metastasis. There were 6 patients who had multiple vertebral fractures due to severe osteoporosis. We decided which vertebrae to treat using the MR images and corresponding clinical findings including severe tenderness on the spinous process.

We used a manufactured kit from American OsteoMedix (Leesburg, VA, USA) for initial consecutive seven patients, which had a larger gauge introducer for a very low pressure delivery of viscous PMMA. The gauge introducer could contain 1.5ml of PMMA for thoracic type. We are currently using a manufactured kit from Tae Yeon Medical Company (Incheon, Korea), which allow injection of maximum 2.2ml of PMMA at a time.

Percutaneous vertebroplasty was performed in an operating room under sterile conditions. Upon completing the informed consent process, the patient is placed in the prone position on the fluoroscopy table. Blood pressure and pulse oximetry are monitored continuously. Intravenous Pethidine (25mg) is given for analgesia; 1g of cefazolin is administered intravenously at the start of the procedure. Under strict sterile conditions, the skin overlying the vertebral body is cleaned and draped.

The posterolateral extrapedicular PVBA technique can be performed using a fluoroscopy for all middle thoracic levels. Under anteroposterior fluoroscopic guidance, a line is drawn along the vertical lateral pedicle line and another line is drawn parallel to this vertical line 2.5 to 3.0cm lateral. A transverse line is also made parallel to the inferior end plate of target vertebra 1cm below. The cross point of two lines is the skin entry point (Fig. 1). Before a skin incision is made over the puncture site, local anesthetic consisting of a 1% lidocaine is administered to the skin, the subcutaneous tissues, and the periosteum. After making a punch incision with a scalpel, the guide wire is inserted at a shallow 75° angle off the vertical line, targeting and docking on the ipsilateral lamina under anteroposterior fluoroscopy. Using lateral fluoroscopy, the guide wire is carefully walked along the lamina and is dropped off the lamina approximately 1cm onto the vertebral ridge (target point). After confirmation of the appropriate docking, the guide wire is advanced to a depth of 50% of the vertebral body and verified using anteroposterior fluoroscope. Upon trajectory confirmation, the fluoroscopy is returned to the lateral and the guide wire is advanced to a depth

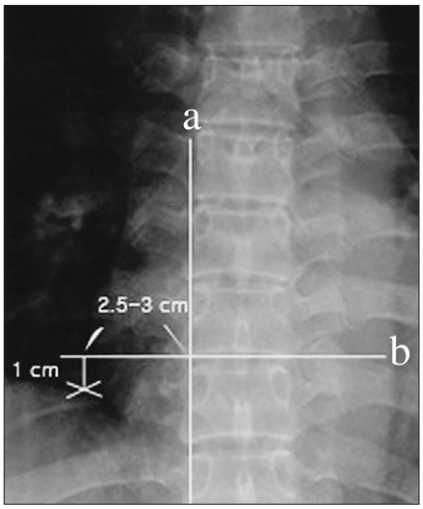

Fig. 1. The initial starting point in the thoracic vertebral body; a longitudinal line is drawn along the lateral pedicle line (a) and a transverse line is also made along the inferior end plate of target vertebra (b). About 2.5 to 3cm lateral from the line "a" and 1cm below from the line "b" is the starting point (white "x").

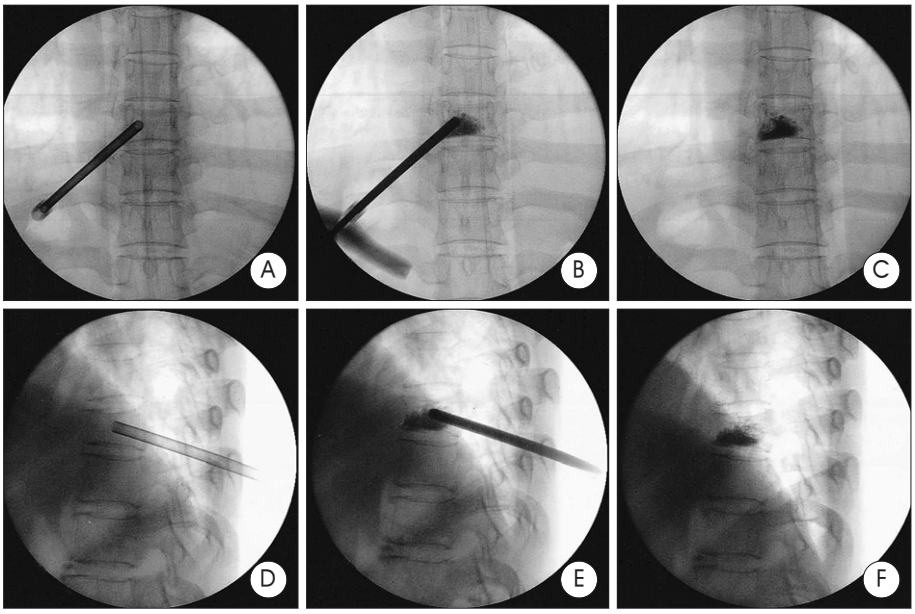

Fig. 2. Percutaneous vertebroplasty utilizing posterolateral extrapedicular PVBA technique for T8 compression fracture in 48-year-old female. A, B, C : Anteroposterior radiographs show a cannula placement through the extrapedicular route into the vertebral body. D, E, F : Lateral photographs showing a cannula placement through the inferior portion of the body and well located PMMA.

of 60-70% of the vertebral body. The second cannula is advanced along the guide wire in order.

After satisfactory needle placement, the PMMA is prepared. We have used 29% barium contained Type I (slow setting) PMMA (Elmdown LTD, London, England). The liquid monomer is added until toothpaste like viscosity is created, which is then injected into the fractured vertebrae under fluoroscopic guidance. PMMA injection is terminated when adequate filling of the vertebral body is achieved, or when significant leakage outside the vertebral body occurs. The amount of injected PMMA was measured by the physician who injected the PMMA by pre-measured gauge introducer. A total volume of 1.5 to 2.5ml of PMMA was injected into the fractured vertebral body (Fig. 2).

Postprocedural care included keeping the patients in bed for approximately 4-6 hours. All of the patients were recommended to wear the appropriate hard brace for 4-6 weeks to prevent further collapse.

We used a visual analogue scale (VAS) to assess each patient's average symptoms, and it was checked immediately after procedure, after 1 week, and each month. Excellent outcome was defined as subjective decrease in pain severity below 2 in a VAS. VAS 3 and 4 were considered as a good result, 5 and 6 as fair result. VAS above 7 was considered as a poor result.

At each follow-up visit, anteroposterior and lateral radiographs of the spine were obtained to assess the morphology of the vertebrae treated and new vertebral collapse. We measured compression rate using the ratio of anterior body height to posterior body height on lateral radiograph and kyphotic angle using Cobb's angle during follow-up period. In case of multilevel fracture, we obtained mean value of each level. The outcome assessment and the radiographic evaluation were performed by the same physician (YJ Cho).

Statistical analysis was performed using SPSS software (version 11.0, Chicago, Illinois). The paired t-test was used to assess any significant difference between baseline and postvertebroplasty data. A p-value of 0.05 or less was considered significant.

Results

The 15 women (75%) and 5 (25%) men in the study were followed for a mean of 120 days (range, 60 to 270 days) and they ranged from 49 to 83 years in age (mean 71.2 years). The mean symptom duration was 15.3 days (range, 4 to 91 days) and the mean BMD score was -3.29±1.04. Causes of trauma included 10 slip down injuries (50%), 4 unknown etiologies (20%), 4 lifting traumas (20%), and 2 fall down injuries (10%). The clinical data of the patients are summarized in Table 1. The treated vertebrae were T5 (1 level), T6 (5 levels), T7 (7 levels), and T8 (9 levels).

Table 1. Summary of patient demographics

Factor	Value
No. of patients	
Total	20
Men	5
Women	15
Age of patients	
Mean ± SD	71.2±8.93
Range	49−83
Duration of symptom (days)	
Mean	15.3
Range	4−91
Mean BMD score	−3.29±1.04

No. : number, SD : standard deviation, BMD : bone marrow density

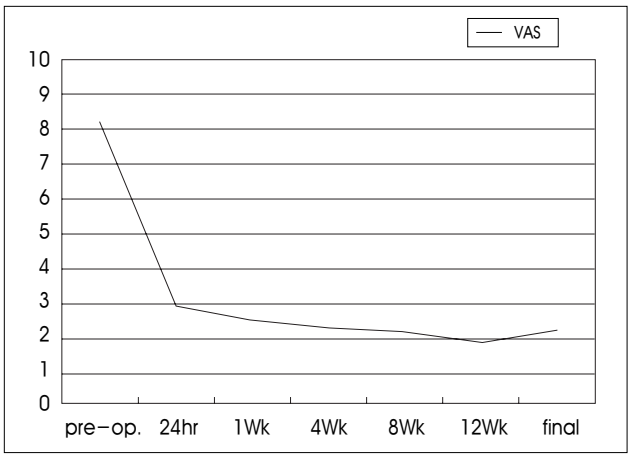

Fig. 3. Longitudinal changes in the mean pain score (as measured by a visual analog scale, $p<0.01$).

The procedures were technically successful in all patients, as defined by effective posterolateral extrapedicular puncture of the vertebral body with instillation of PMMA. The postprocedural mean VAS showed significant improvement from baseline (8.2±0.70 range 7-10) within 24 hours after procedure (2.8±1.15, range 1-5) and at one month (2.4±1.27, range 0-5) and remained improved (2.15±1.14, range 0-5) at the last follow up ($p<0.01$) (Fig. 3). There were no significant changes in any variables from one month to three months. VAS decreased to less than 2 (excellent) in 12 patients (60%) and to 3-4 (good) in 5 patients (35%) of the patients. Most of the pain relief was noted within 24 hour immediately following the procedure. One patient had only mild relief of pain (fair) and was continued on her pretreatment medical regimen. The worsening of pain was not reported.

Compression rate and kyphotic angle were slightly improved after procedure from 18%±13.4 to 16%±13.8 ($p>0.05$) and from 6.9°±6.7 to 6.6°±6.2 ($p>0.05$), respectively. However, further progression of collapse after treatment was observed in 4 levels.

Bone cement leakage was seen outside in 3 (13.7%) of 22

vertebrae treated. The leakage was within the intervertebral disc in 2 (9.1%) cases and lateral side of the vertebra through the fractured cleft in 1 (4.5%). However, there was no case of leakage to epidural space or neural foramen. The major complications occurred related to the procedure including segmental artery injury or pneumothorax were not observed.

Discussion

Percutaneous vertebroplasty, which was designed for treating aggressive hemangiomas, bone metastases, and myeloma[1,20], has been increasingly used for the management of painful osteoporotic vertebral fractures[3,5,7,11,15,21,24]. Percutaneous approach to the middle thoracic vertebrae, however, is difficult because of the small size of the pedicle and vertebral anatomy in the thoracic vertebrae. According to one cadaveric study, the narrowest pedicle width was T5 level with a 4.5mm mean width (range : 3.0-7.0) and T6 through T8 levels also had narrow pedicle width (mean : T6; 5.2, T7; 5.3, T8; 5.9)[26]. The pedicle size of the middle thoracic vertebra especially in small oriental women, might be smaller than the these data and it would be more difficult to gain access through the transpedicular route to perform a vertebroplasty. Because of this reason, some clinicians have avoided to do the procedure by the transpedicular approach in patients with osteoporotic vertebral compression fracture(s) in the middle thoracic vertebrae.

The percutaneous vertebroplasty utilizing PVBA technique was recently developed for safe cement delivery and easy access to the center of the fractured vertebra[12,16]. This PVBA technique utilizing posterolateral extrapedicular approach is useful even in middle or upper thoracic vertebra with a readily identifiable target along the costotransverse process plane providing a safe pathway for access to the anterior vertebral body. It is also possible with the "low pressure-high viscosity" bone cement injection, because this procedure uses relatively large diameter cannula, which can decrease the serious risk of bone cement leakage and amount of bone cement injection. Moreover, this technique can be utilized for gaining access to the vertebral body through a single percutaneous incision.

The PVBA technique can be performed on all thoracic and lumbar levels, but the angle of access in the thoracic vertebra is different from the lumbar level; the starting points are more medial to avoid possible pneumothorax. In thoracic cases they were always apprised of this additional potential risk and the possible need for a chest tube. For the initial several cases, we used across point between 2.5cm lateral away from the lateral vertical pedicle line and parallel transverse line to the low endplate as a starting point. After then we moved the point to a more lateral point, 3cm lateral away from the lateral pedicle line, and more caudally, 1cm below the inferior endplate of target vertebra, because it was easier to access to center of the fractured vertebra with this technique.

Dean et al.[4] advocated that the pattern of bone cement distribution was an important factor to restore the strength of the vertebra. The most effective bone cement location is near the posterior vertebral body wall[25]. Achieving successful bone cement fill in this location is, however, technically demanding, because the risk of leakage into the spinal canal increases during posterior bone cement flow that can result in neurologic complication. The center of the vertebra may be the most ideal bone cement location as a target site except near the posterior vertebral body wall, because it can avoid bone cement leakage and restore the strength of the vertebra more effectively. With PVBA technique it is possible to inject the PMMA into the vertebra more centrally because of its posterolateral trajectory. It may be one of the important advantages of this technique.

Several clinical data suggest that pain relief can be provided with the injection of smaller volumes of cement than previously thought necessary, consistent with the current results[3,11,16]. Based on the experience with posterior stabilization systems[8,14], one possible concern with overfilling is that an overly stiff vertebra body can compromise the kinematics of the surrounding motion segments. Many biomechanical and clinical studies also have found that there is no relationship between percentage filling of a lesion and clinical outcome[3,4,13,16,17,19]. Thus, the trend has been to place smaller volumes of bone cement rather than trying to fill the entire vertebral body and increase the risk of bone cement leakage. Small amount of bone cement (14% fill or 3.5cm^2) can restore stiffness to the predamaged value[17]. We used relatively small amount of bone cement in the present study than in those previous studies. Use of a small amount of bone cement appears to improve the safety of the procedure. However, there were 4 levels that had developed further progression of collapse with variable range from 2% to 14% at the last follow-up period. All of the progression of collapse revealed within the initial one month after procedure. It might be influenced from relatively small amount of bone cement injection. However, the number of our patients in our study is too small to draw any statistical conclusions in the risk of further collapse, and further studies and long term follow-up are necessary. Nevertheless, our data suggest that a relatively small amount of bone cement injection can restore vertebral compressive stiffness and relief pain immediately.

Cement leakage is a frequent event of percutaneous vertebroplasty[7,11,23], but it rarely results in a clinical complication if the leaked volumes are small[7,15,22,23]. Leakage may track into a variety of anatomical structures, including spinal canal, neural foramen, intervertebral disc, pre- and paravertebral soft tissues, and vascular structures such as the prevertebral veins, epidural veins, inferior vena cava, and aorta[3,7,11,15,18,19,21,24]. Bone cement

leakage into the adjacent pre- and paravertebral soft tissues, however, is almost always asymptomatic. In some patients, bone cement traverses endplate fractures and enters the disk space, which, in our experience, is of no clinical significance. Small perivertebral venous leakages are also usually not regarded as being clinically significant[15,22]. The most serious complication of percutaneous vertebroplasty is inadvertent leakage of bone cement into the spinal canal or neural foramen. This complication is frequently related to increasing volume of injected bone cement[9,20]. Although bone cement leakage is tolerated in the majority of patients, it is also the main source of clinical complications of this procedure. Attempts at avoiding and preventing its occurrence should be made during performance of percutaneous vertebroplasty. PVBA technique can decrease the risk of leakage by allowing application of a more viscous PMMA using large diameter cannula. And, a small amount of bone cement may offer a theoretical advantage of decreasing risk of bone cement leakage with their technique.

There is concern about the potential risk of pneumothorax due to the posterolateral trajectory of this PVBA technique. We were also concerned about the complication of pneumothorax at the beginning of the procedure. We have performed approximately 140 thoracic vertebroplasty using this PVBA technique, but we have not had any experience of pneumothorax yet. There were no other severe treatment related complications. The vertebral deformity did not progress in any of the injected vertebrae. The authors concluded that vertebroplasty utilizing the PVBA technique for the patients with osteoporotic vertebral compression fracture was safe and efficacious over both the short and long term.

Conclusion

Percutaneous approach to the thoracic vertebra is difficult because of the small pedicle size and vertebral body anatomy especially in the middle thoracic vertebrae. The posterolateral percutaneous vertebral body access technique (PVBA) avoids the pedicle and provides direct access to the vertebral body. With PVBA technique, it is also possible with the "low pressure-high viscosity"cement injection, because it uses large diameter cannula, which can make less serious bone cement leakage. Complications occur rarely and are potentially avoidable with application of a meticulous technique. Thus, the PVBA technique is considered useful in the management of painful vertebral compression fracture in the middle thoracic vertebrae.

References

1. Barr JD, Barr MS, Lemley TJ, McCann RM : Percutaneous vertebroplasty for pain relief and spinal stabilization. **Spine 25** : 923-928, 2000
2. Bostrom MPG, Lane JM : Future directions: augmentation of osteoporotic vertebral bodies. **Spine (Supple) 22** : 38-42, 1997
3. Cotten A, Dewatre F, Cortet B, Assaker R, Leblond D, Duquesnoy B, et al : Percutaneous vertebroplasty for osteolytic metastases and myeloma : effects of the percentage of lesion filling and the leakage of methyl methacrylate at clinical follow-up. **Radiology 200** : 525-530, 1996
4. Dean JR, Ison KT, Gishen P : The strengthening effect of percutaneous vertebroplasty. **Clin Radiol 55** : 471-476, 2000
5. Deramond H, Wright NT, Belkoff SM : Temperature elevation caused by bone cement polymerization during vertebroplasty. **Bone 25** : 17S-25S, 1999
6. Diamond TH, Champion B, Clark WA : Management of acute osteoporotic vertebral fractures : a nonrandomized trial comparing percutaneous vertebroplasty with conservative therapy. **Am J Med 114** : 257-265, 2003
7. Do HW, Kwon YJ, Yang JY, Choi CS, Ju MB : The analysis of polymethylmethacrylate leakage after vertebroplasty for vertebral body compression fractures. **J Korean Neurosurg Soc 35** : 478-482, 2004
8. Ferguson RL, Tencer AF, Woodard P, Allen BL Jr : Biomechanical comparisons of spinal fracture models and the stabilizing effects of posterior instrumentations. **Spine 13** : 453-460, 1988
9. Grados F, Depriester C, Cayrolle G, Hardy N, Deramond H, Fardellone P : Long-term observation of vertebral osteoporotic fractures treated by percutaneous vertebroplasty. **Rheumatology 39** : 1410-1414, 2000
10. Hide IG, Gangi A : Percutaneous vertebroplasty : history, technique and current perspective. **Clin Radiol 59** : 461-467, 2004
11. Jensen ME, Evans AJ, Mathis JM, Kallmes DF, Cloft HJ, Dion JE : Percutaneous polymethylmethacrylate vertebroplasty in the treatment of osteoporotic vertebral body compression fractures : technical aspects. **AJNR Am J Neuroradiol 18** : 1897-1904, 1997
12. Kang JH, Kuh SU, Shin ZZ, Cho YE, Yoon YS, Chin DK : The effectiveness of osteoplasty system (vertebroplasty using large cannula-low pressure delivery system) in compression fracture and other spinal pathology. **J Korean Neurosurg Soc 38** : 259-264, 2005
13. Komemushi A, Kariya TS, Kojima KH, Shomura Y, Sawada S : Percutaneous vertebroplasty for compression fracture : analysis of vertebral body volume by CT volumetry. **Acta Radiologica 46** : 276-279, 2005
14. Kornblatt MD, Casey MP, Jacobs RR : Internal fixation in lumbosacral spine fusion. A biomechanical and clinical study. **Clin Orthop Relat Res** : 141-150, 1986
15. Lee JU, Ryu KS, Park CK, Choi YK, Park CK, Ji C, et al : Percutaneous polymethylmethacrylate vertebroplasty in the treatment of osteoporotic thoracic and lumbar vertebral body compression fractures : outcome of 159 patients. **J Koren Neurosurg Soc 30** : 173-179, 2001
16. Lee KS, Cho YJ, Choi JH, Cho SM, Ryu KS, Ahn MS : A small amount of bone cement injected vertebroplasty utilizing percutaneous vertebral body access technique for osteoporotic vertebral fractures. **Korean J Spine 2** : 333-341, 2005
17. Leibschner MAK, Rosenberg WS, Keaveny TM : Effects of bone cement volume and distribution on vertebral stiffness after vertebroplasty. **Spine 26** : 1547-1554, 2001
18. Moreland DB, Landi MK, Grand W : Vertebroplasty : techniques to avoid complications. **Spine 1** : 66-71, 2001
19. Mousavi P, Roth S, Finkelstein J, Cheung G, Whyne C : Volumetric quantification of cement leakage following percutaneous vertebroplasty in metastatic and osteoporotic vertebrae. **J Neurosurg 99** : 56-59, 2003
20. Murphy KJ, Deramond H : Percutaneous vertebroplasty in benign and malignant disease. **Neuroimaging Clin N Am 10** : 535-545, 2000
21. Noh CH, Yi JS, Lee HJ, Yang JH, Lee IW, Kim MC : Effect of percutaneous vertebroplasty with polymethylmethacrylate to osteoporotic spinal compression fractures and bursting fractures. **J Korean Neurosurg Soc 35** : 365-371, 2004
22. Perez-Higueras A, Alvarez L, Rossi RE, Quinones D, Al-Assir I : Percutaneous vertebroplasty : long-term clinical and radiological outcome. **Neuroradiology 44** : 950-954, 2002
23. Ryu KS, Park CK, Kim MC : Dose-dependent epidural leakage of polymethylmethacrylate after percutaneous vertebroplasty in patients with osteoporotic vertebral compression fractures. **J Neurosurg (Supple) 96** : 56-61, 2002
24. Truumees E, Hilibrand A, Vaccaro AR : Percutaneous vertebral augmentation. **Spine J 4** : 218-229, 2004
25. Tschirhart CE, Sandra ER, Whyne CM : Biomechanical assessment of stability in the metastatic spine following percutaneous vertebroplasty : effects of cement distribution patterns and volume. **J Biomech 38** : 1582-1590, 2005
26. Zindrick MR, Wiltse LL, Doornik A, Widell EH, Knight GW, Patwardhan AG, et al : Analysis of the morphometric characteristics of the thoracic and lumbar pedicles. **Spine 12** : 160-166, 1987